Downloaded from ajronline.org by 2800:2331:7300:162:cd27:c8e:3456:2d47 on 11/22/26 from IP address 2800:2331:7300:162:cd27:c8e:3456:2d47. Copyright ARRS. For personal use only; all rights reserved

AJR FOCUS ON:

How I Diagnose Meniscal Tears on Knee MRI

Arthur A. De Smet[1]

OBJECTIVE. The goal of this article is to summarize the literature about the diagnosis of meniscal tears on MRI including the normal appearance of the meniscus and the appearance of the various types of meniscal tears. In addition, I discuss my experience with the causes of errors in the MR diagnosis of meniscal abnormalities and the nuances of meniscal abnormalities that can mimic a meniscal tear.

CONCLUSION. MRI is a highly accurate imaging method for diagnosing meniscal tears. To avoid errors in diagnosing meniscal tears, those interpreting MR examinations of the knee need to be aware of the attachments of the menisci and the normal variations in meniscal anatomy that may resemble a meniscal tear. In addition, by being aware of the patterns of meniscal tears, it is easier to diagnose the less common tears.

Keywords: knee, meniscal anatomy, meniscal tear, MRI, normal variants

DOI:10.2214/AJR.12.8663

Received January 26, 2012; accepted after revision March 22, 2012.

[1]Department of Radiology, University of Wisconsin School of Medicine and Public Health, 600 Highland Ave, E3/311, Madison, WI 53792-3252. Address correspondence to A. A. De Smet (adesmet@uwhealth.org).

CME
This article is available for CME credit.

AJR 2012; 199:481–499

0361–803X/12/1993–481

© American Roentgen Ray Society

This article summarizes my research and clinical experience in the diagnosis of meniscal tears using knee MRI. I have referenced the recent literature and give my opinions as well as unpublished clinical observations when definitive research is not available on specific topics.

When evaluating a knee MR examination, I study the medial and lateral menisci first on the sagittal images and then on the coronal images because sagittal images are the most useful in diagnosing meniscal tears. In one study, 97% of medial and 96% of lateral meniscal tears could be identified on sagittal MR images [1]. In a later study, 82% of meniscal tears were definitively diagnosed on sagittal images alone [2].

Menisci should have low signal intensity on MR images because of their fibrocartilage composition, but they may have central globular or linear increased signal intensity secondary to internal mucinous degeneration [3]. In addition, the menisci in asymptomatic children have a 66% frequency of internal signal on MRI and that signal is presumed to reflect normal vascularity [4].

Another proposed cause of increased intrameniscal signal is a meniscal contusion after acute trauma [5]. I reserve the diagnosis of meniscal contusion for menisci with internal signal equal to fluid on T2-weighted images in patients with a recent episode of trauma.

Knowing the distribution of meniscal tears is helpful in assessing the menisci on MRI. In an arthroscopic series of 1086 medial meniscal tears, the posterior horn was involved in 98% of the torn medial menisci [6]. Because of this tear distribution, I am cautious in diagnosing a medial meniscal tear that does not involve the posterior horn. However, lateral meniscal tears are more varied in location: Investigators who conducted an arthroscopic series of 399 lateral meniscal tears reported that tears involved the posterior horn in 55%, the body or the body and anterior horn in 29%, and the anterior horn alone in 16% [6].

MR Criteria for the Diagnosis of Meniscal Tears

Despite the improvement in the quality of knee MR images in the past 25 years, the two primary MR criteria for the diagnosis of meniscal tears have not changed since the late 1980s. These criteria are, first, contact of intrameniscal signal with the superior or the inferior surface of a meniscus (or with both surfaces) and, second, distortion of the normal appearance of a meniscus [7].

To diagnose a meniscal tear using these criteria, it is essential to understand how normal variations in the shape of the menisci and their attachments compare with the MR appearance of a meniscal tear.

Downloaded from ajronline.org by 2800:2331:7300:162:cd27:c8e:3456:2d47 on 11/22/26 from IP address 2800:2331:7300:162:cd27:c8e:3456:2d47. Copyright ARRS. For personal use only; all rights reserved

Normal Shape and Attachments of the Medial Meniscus

The anterior horn, body, and posterior horn of the menisci have a triangular cross-sectional appearance on both coronal and sagittal MR images. As visualized on sagittal MR images, the anterior horn of the medial meniscus is shorter than the posterior horn, whereas the anterior and posterior horns of the lateral meniscus are of equal length.

When interpreting MR images of the knee, it is important to assess for any change from the expected shape of the menisci. The anterior and posterior horns of both menisci and the body of the lateral meniscus have an isosceles triangle appearance, whereas the body of the medial meniscus has an equilateral triangle appearance and is shorter than the anterior horn. Normally the superior and inferior surfaces of the menisci are equal in length. A change from this configuration suggests the presence of a tear (Fig. 1A).

However, a meniscus can exhibit a "meniscal flounce," which is a rippled appearance similar to a ruffled item of clothing (Fig. 2). A meniscal flounce is uncommon on MRI, being seen in only 0.16% of medial menisci and 0.03% of lateral menisci in one clinical series [8]. However if the knee is flexed, a flounce can be seen on MRI in 5% of menisci [9]. During knee arthroscopy, a flounce is almost always noted in an intact medial meniscus because the knee is flexed during the procedure [10].

Anterior Root of the Medial Meniscus

The cross-sectional shape of the medial meniscus changes in the regions of the anterior and posterior roots. The medial meniscus becomes flattened as it transitions into the anterior root. The anterior root has a variable attachment, with 82% of individuals having an attachment on the flat surface of the tibia anterior to the tibial eminence [11]. Three percent of individuals do not have an anterior root attachment to the tibia, but the meniscus is stabilized by the transverse meniscal ligament connecting the anterior horns of the medial and lateral menisci [11].

The most distinctive normal variant—seen in 15% of individuals—is an anterior root attachment on the anterior margin of the tibia near the midline [11]. As a result of this anterior attachment, the meniscus at the midportion of the medial tibial plateau lies anterior to the tibial margin suggesting pathologic anterior subluxation (Figs. 3A and 3B). This subluxation is a normal variation without proven clinical significance.

An infrequent finding at the anterior horn of the medial meniscus adjacent to the root is a ligament extending from the meniscus to the anterior cruciate ligament (ACL). This attachment is visualized on MRI only occasionally; however, when it is thick, it may appear to be a displaced meniscal fragment (Fig. 4). In a comprehensive study of 1326 patients, this variant attachment was found in 2.3% of the patients at arthroscopy with 60% of the ligaments identifiable on knee MRI [12].

Posterior Root of the Medial Meniscus

As the posterior horn of the medial meniscus extends toward its root attachment, it also loses its isosceles triangular shape. Initially, it becomes a shortened triangle and then flattens at the attachment. As a normal variation, the posterior root may have a fissured appearance that should not be mistaken as evidence of a meniscal tear (Fig. 5). When visualized on coronal images, the posterior root appears as a band of low signal intensity with parallel sides that attaches to the tibia behind the tibial eminence either horizontally or with an inferiorly directed band.

Normal Shape and Attachments of the Lateral Meniscus

The lateral meniscus has an isosceles triangle appearance in its anterior horn, body, and posterior horn but has considerably more complex anterior and posterior attachments than the medial meniscus.

Transverse Meniscal Ligament

The transverse meniscal ligament, also called the "geniculate ligament," extends from the anterior horn of the medial meniscus to attach to the anterior horn of the lateral meniscus [13]. At the attachment of the ligament onto the superior surface of the anterior horn of the lateral meniscus, there is commonly a high-signal-intensity line. This line can be mistaken for an anterior horn tear [14].

Anterior Root of the Lateral Meniscus

The anterior root of the lateral meniscus differs from the anterior root of the medial meniscus because it often has a prominent fissured appearance similar to the posterior root of the medial meniscus (Fig. 6). This fissured appearance on MRI is caused by fibrofatty tissue interposed between the insertional collagenous fibers of the anterior root as well as interposed fibers of the ACL insertion [15]. I have noted that the anterior horn can have a horizontal division as it passes to the root (Fig. 7), although this finding has not been described to date in the literature.

Popliteomeniscal Fascicles of the Lateral Meniscus

The major attachments of the posterior horn of the lateral meniscus are the popliteomeniscal fascicles and the meniscofemoral ligaments. The popliteomeniscal fascicles are fibrous bands covered by synovium that attach the posterior horn of the lateral meniscus to the joint capsule.

The most commonly described popliteomeniscal fascicles are the anteroinferior, posterosuperior, and posteroinferior [16]. The anteroinferior and posterosuperior fascicles were seen on MRI in 97% of patients who had a normal lateral meniscus at arthroscopy [17]. That same study found that the fascicles are best seen on T2-weighted images but that the frequency of visualization was not changed in the presence of an effusion. Disruption of these fascicles in a cadaver study was shown to cause meniscal instability [18]. The posteroinferior fascicle extends from the inferior margin of the lateral meniscus at the medial edge of the popliteal hiatus. Because the fascicle is seen in cross section as it passes from the meniscus to its capsular insertion, it may resemble an inferior torn flap of the meniscus (Fig. 8).

The major landmark that can be used to identify these fascicles is the popliteal hiatus. The hiatus is the opening in the posterior capsule through which the popliteus tendon enters into the joint behind the lateral meniscus. At the medial aspect of the hiatus, the popliteus tendon passes just superior to the posteroinferior fascicle. Then, as the tendon passes laterally, it passes beneath the posterosuperior fascicle and above the anteroinferior fascicle.

Meniscofemoral Ligaments of the Lateral Meniscus

The other major attachments of the posterior horn of the lateral meniscus are the meniscofemoral ligaments with the Humphry ligament anterior to the posterior cruciate ligament (PCL) and the Wrisberg ligament posteriorly (Figs. 9A and 9B). Both ligaments are routinely identified in anatomic dissections of the knee but only one or both ligaments may be identified on MR examinations of patients [19]. Because these ligaments arise from the lateral meniscus before their attachment onto the inner margin of the medial femoral condyle, they can

Downloaded from ajronline.org by 2800:2331:7300:162:cd27:c8e:3456:2d47 on 11/22/26 from IP address 2800:2331:7300:162:cd27:c8e:3456:2d47. Copyright ARRS. For personal use only; all rights reserved

appear as an apparent cleft or distortion in the superior aspect of the posterior horn (Fig. 9). Occasionally the meniscofemoral Humphry ligament can appear as a large low-signal-intensity structure within the notch that may resemble a displaced meniscal fragment (Fig. 10). Following the course of the ligaments on sequential sagittal MR images allows differentiation of the normal ligament from a meniscal tear or displaced fragment.

Posterior Root of the Lateral Meniscus

The posterior root of the lateral meniscus is a particularly difficult area to assess on MRI for a tear. As the posterior horn extends medially into the root, the meniscus rises from the level of the lateral tibial plateau to attach more superiorly on the tibial eminence. This superiorly directed course can result in increased signal on MRI within this area of the lateral meniscus because of the magic angle effect seen in collagen fibers, which are oriented obliquely to the magnetic field [19]. In addition, the posterior root is oriented at 45° to the sagittal and coronal planes so that any abnormality of the root is not visualized in the optimal right-angle orientation to the image planes [20].

As the lateral meniscus passes over the lateral tibial spine toward its attachment, it has a crescentic appearance and then appears as a thin band at its attachment. I have found that fluid-sensitive images are more specific than proton density–weighted images for diagnosing lateral posterior root tears. Proton density–weighted images often show increased signal in the root due to the magic angle effect and the oblique orientation of the root to coronal and sagittal images [21].

Uncommon Medial and Lateral Meniscal Variants

Those who interpret knee MR examinations should be aware of the MR appearances of normal meniscal variants that could be confused with meniscal abnormalities. These variants include a discoid meniscus, ring lateral meniscus, meniscal ossicle, and oblique meniscomeniscal ligament.

Discoid Meniscus

Although the normal meniscus is triangular in cross section with a C-shaped configuration, occasionally an individual may have a meniscus that extends farther onto the articular surface of the tibia. This variant is called a "discoid meniscus" [22], and it may be complete or incomplete according to the Watanabe classification. Discoid menisci are 10–20 times more common in the lateral meniscus than in the medial meniscus [22].

A complete discoid meniscus is easily recognized on MR images because it has parallel superior and inferior surfaces and extends into or near the notch with a disk configuration. An incomplete discoid meniscus has a trapezoidal appearance and may involve only one horn of the meniscus or may extend only partly onto the articular surface of the tibia. In a study of the MR appearance of 38 arthroscopically confirmed discoid menisci, an incomplete discoid meniscus could be differentiated from a normal meniscus when the meniscus extended more than 14 mm into the joint as measured on a midline coronal image [23] (Fig. 11).

Occasionally it can be difficult to diagnose a tear in a discoid meniscus on MRI because the meniscus may have diffuse internal signal that contacts one or both articular surfaces of the meniscus without the presence of a tear. In two studies correlating the MR and arthroscopic findings of patients with discoid lateral menisci, diffuse MR signal to the articular surface had a positive predictive value of only 57% and 78% for a tear [24, 25]. On the basis of these studies, I interpret a discoid meniscus with diffuse signal to the surface as 60–80% likely to be torn (Fig. 12). In contrast, linear signal to the surface of a discoid meniscus is almost always associated with a meniscal tear (Fig. 12).

Ring Lateral Meniscus

A ring lateral meniscus is a rare meniscal variant in which the lateral meniscus is in the shape of a complete ring [26]. A ring medial meniscus is even more rare and has been reported in only one patient to date [27]. Because of the presence of meniscal tissue adjacent to the notch, those interpreting an MR examination might misdiagnose this tissue as a displaced meniscal fragment. The key MR features that differentiate a ring lateral meniscus from a displaced meniscal fragment are the perfect isosceles triangle appearance of the meniscus within the central portion of the joint and the absence of a defect in the remainder of the meniscus (Fig. 13).

Meniscal Ossicle

A meniscal ossicle is a focal area of ossification within a meniscus that is most common in the posterior horn of the medial meniscus. Meniscal ossicles may be asymptomatic or may be symptomatic because of mass effect or an associated meniscal tear. Meniscal ossicles are uncommon, with a meniscal ossicle noted in 0.15% of 1287 knee MR examinations [28]. Ninety percent of the ossicles in that study were in males and only one third of the menisci with ossicles had associated tears. The most commonly suggested cause for these ossicles is that they represent posttraumatic ossification. The ossicle may contain central fatty marrow or may be uniformly calcified.

Oblique Meniscomeniscal Ligament

Occasionally a ligament will be noted extending from the anterior horn of one meniscus to attach to the posterior horn of the contralateral meniscus. Medial and lateral oblique meniscomeniscal ligaments have been identified with the ligament named according to its anterior attachment. The reported prevalence has ranged from 1% to 4% in anatomic and surgical series [29]. Similar to the potential error when interpreting MR images of a ring lateral meniscus, a potential error in MR diagnosis is mistaking this central low-signal-intensity structure for a displaced meniscal fragment. The correct diagnosis of an oblique meniscomeniscal ligament rather than the diagnosis of a displaced tear is made by recognizing the continuity of this ligament as it extends from its anterior to its posterior attachments and its presence in both the medial and lateral compartments of the knee (Fig. 14).

Types of Meniscal Tears

A commonly used surgical classification of meniscal tears includes the following types: horizontal, longitudinal, radial, bucket handle, displaced flap, and complex [6]. Those who interpret knee MR examinations need to be aware of the MR appearance of each type of tear to increase their accuracy of diagnosis of meniscal tears and to precisely describe the tear for the treating orthopedic surgeon [30].

Horizontal Tears

Horizontal tears are common, representing 32% of the medial and lateral meniscal tears in a series of 2179 knee arthroscopy patients [6]. Although these tears are often confined to the posterior horn, they may extend into the body and anterior horn of the meniscus. Patients with horizontal meniscal tears often recall no specific episode of trauma but report new or increased knee pain after increased physical activity. Because these tears usually

Downloaded from ajronline.org by 2800:2331:7300:162:cd27:c8e:3456:2d47 on 11/22/26 from IP address 2800:2331:7300:162:cd27:c8e:3456:2d47. Copyright ARRS. For personal use only; all rights reserved

occur in patients more than 40 years old without an initiating trauma, they are sometimes classified as degenerative tears. However, it is better to describe the pattern of tear rather than use a term ascribing a cause to the tear.

Histologic studies of cadaveric menisci with MR correlation have found that internal meniscal signal is caused by collagen fiber degeneration with myxoid and eosinophilic deposits [3]. Early reports on meniscal MRI suggested that the increased frequency of internal meniscal signal with increasing age was a precursor to the development of a horizontal tear. However, multiple studies subsequently found that patients with intrameniscal signal on MRI do not have an increased likelihood of developing a meniscal tear or significant knee disability compared with patients without internal meniscal signal on MRI [31–34].

Horizontal tears appear on MRI as a horizontally oriented line of increased intrameniscal signal that extends to the superior or inferior surface of the meniscus near the free edge (Fig. 15). The surface extension may be subtle in some patients because these tears have extensive fibrillation on the surface. This fibrillation results in interdigitated surface fibers so the internal signal may not definitely contact the meniscal surface on MRI. When it is difficult to be certain of surface contact of the internal signal, I am more confident of the diagnosis of a horizontal meniscal tear when the intrameniscal signal has the intensity of fluid on T2-weighted images (Fig. 15B).

Longitudinal Tears

Longitudinal tears have a vertical orientation on MR images of the menisci and extend parallel to the circumference of the meniscus. These tears are almost always associated with a significant knee injury, especially an ACL tear. In one study, 17% of patients with an acute ACL tear had a medial meniscal peripheral longitudinal tear and 10% had a lateral peripheral longitudinal tear with these tears often having a bucket-handle displacement [35].

Longitudinal tears almost always involve the posterior horn in both the medial and lateral menisci. They are diagnosed on MRI by the presence of a vertical line of increased signal intensity contacting the superior, inferior, or both surfaces of the meniscus (Fig. 16).

It is sometimes difficult to identify peripheral longitudinal tears in the posterior horn of the lateral meniscus because of the complex posterior attachments of the meniscus. In these cases, the tear is often more conspicuous on sagittal T2-weighted images (Fig. 17). In addition, there are several MR findings that suggest the presence of a lateral meniscal tear. Disruption or the absence of the posterosuperior popliteomeniscal fascicle has a 79–100% positive predictive value for an arthroscopically confirmed tear of the posterior horn of the lateral meniscus [36, 37]. In another study, a peripheral longitudinal tear of the lateral meniscus was likely if the meniscofemoral ligament attachment to the lateral meniscus extended 14 mm or more lateral to the PCL [38].

The central fragment of a meniscus with a peripheral longitudinal tear may displace centrally into the joint creating a bucket-handle tear. The displaced fragment is considered to resemble the lifted up handle of a bucket. Various signs have been used to describe this centrally displaced fragment including the double PCL sign and flipped meniscus sign [39–41] (Figs. 18 and 19).

Radial Tears

Radial tears are vertically oriented tears that arise from the free edge of a meniscus and extend into the meniscus. Various signs have been used to describe the appearance of a radial tear on MRI including the "cleft" sign, "truncated meniscus" sign, "ghost meniscus" sign, and "marching cleft" sign [42].

The most common locations for radial tears are the posterior horn in the medial meniscus and at the junction of the body and anterior horn in the lateral meniscus. Radial tears in the posterior horn of the medial meniscus are diagnosed on MRI by noting a vertical cleft of increased signal intensity contacting the meniscal surface on coronal images and a blunted or absent meniscus on sagittal images (Figs. 20 and 21).

A radial tear in the medial meniscus is often associated with medial extrusion of the body of the medial meniscus beyond the margin of the tibia [43]. The body of the medial meniscus extrudes because a radial tear disrupts the circumferential fibers of the meniscus [44]. These fibers act like hoops on a wooden stave barrel and resist the outward stresses on the meniscus when bearing weight on the knee. With disruption of the fibers by a radial tear, the body of the meniscus is displaced medially (Fig. 21). When the periphery of the body of the medial meniscus is displaced 3 mm or more beyond the edge of the tibial plateau, meniscal extrusion is present. When medial meniscal extrusion is noted on MRI, the posterior horn and root of the medial meniscus should be carefully evaluated for a radial tear.

Radial tears at the junction of the body and anterior horn of the lateral meniscus may be difficult to diagnose on MRI because of the oblique orientation of the tear relative to the coronal and sagittal plane images (Fig. 22). My colleagues and I have found that these tears are easier to diagnose now that we have decreased the image interslice gap from 1.5 to 0.5 mm and decreased the image thickness from 3 to 2 mm on the 3-T knee scans. Investigators have reported that thin axial MR images may be helpful in the diagnosis of all types of meniscal tears [45]. However, in my experience, 0.8- to 1.0-mm axial images have been useful primarily in confirming radial tears suspected but not definitively diagnosed on coronal and sagittal images (Fig. 22A).

Complex Tears

Complex meniscus tears are those in which the tear extends in more than one plane creating separate flaps of meniscus [6]. However, many meniscal tears have a small component of a tear that extends into a second plane. In these situations, I describe a tear as having one predominant plane with a small component in a second plane. I reserve the term "complex tear" for a tear that has extensive distortion and multiple lines of signal to the meniscal surface indicating that multiple flaps will be found at arthroscopy (Fig. 23).

When a piece of a torn meniscus is displaced or can be displaced by a probe during arthroscopy, that piece is termed a "flap." A horizontal tear will always have a superior flap and an inferior flap, but a vertical extension of the tear can create additional flaps. A radial tear that passes perpendicular to the circumference will not have a flap, but an oblique radial tear results in a free-edge flap, sometimes called a parrot-beak tear because of the curved beak appearance of the flap noted at arthroscopy. The term "parrot-beak tear" should be reserved for arthroscopy reports and not used in the MR description of a meniscal tear pattern.

Displaced Flap Tears

If a meniscal tear results in a fragment displaced away from the site of tear, it is important on knee MRI to identify the fragment location before arthroscopy. It can sometimes be difficult to find the displaced fragment at arthroscopy; if it is not removed, there is often persistent knee pain and locking.

A shortened meniscus on coronal or sagittal MR images is often caused by a displaced flap

Downloaded from ajronline.org by 2800:2331:7300:162:cd27:c8e:3456:2d47 on 11/22/26 from IP address 2800:2331:7300:162:cd27:c8e:3456:2d47. Copyright ARRS. For personal use only; all rights reserved

tear but can be seen with radial tears, as discussed earlier; a partially resected meniscus; or a macerated meniscus. When a meniscus is resected, it appears shortened, often with an irregular free edge on MRI. A macerated meniscus is a meniscus in which there is only a small meniscal remnant. Maceration can occur if there is severe cartilage loss and an unstable knee that result in grinding away of the meniscus by the exposed subchondral bone.

However, in the absence of prior meniscal surgery, severe overlying cartilage loss, or a radial tear, the most common cause for a shortened meniscus on MRI is a meniscal tear with a displaced fragment. To locate the displaced fragment, one needs to be aware of where these fragments are most commonly found.

Approximately two thirds of medial meniscus displaced fragments are found in the posterior aspect of the joint near or behind the PCL, whereas the remaining cases are usually in the superior or inferior recesses above and below the body of the medial meniscus [46, 47] (Figs. 1B and 1C).

In contrast to displaced fragments of the medial meniscus, displaced lateral meniscal fragments are seen equally frequently in the recesses of the body of the meniscus and in the posterior aspect of the joint [46]. The posteriorly displaced fragments often extend into the popliteal hiatus (Fig. 24).

Posterior Root Tears

In recent years, posterior root tears have received increasing attention in both the arthroscopic and MR literature [48]. Medial root tears are usually radial in type and are often associated with meniscal extrusion as noted earlier. The MR findings of a medial posterior radial root tear are shortening or absence of the root on sagittal images and a vertical fluid cleft on coronal fluid-sensitive images. The reported MR sensitivity and specificity for the diagnosis of a medial root tear are 86–90% and 94–95%, respectively [49, 50].

When there is an ACL tear, particular attention should be paid on MRI to the lateral meniscus because in one study lateral meniscal root tears were found in 8% of patients with ACL tears but in only 0.8% of patients without an ACL tear [21]. When a radial tear is present in the posterior root of the lateral meniscus, the appearance may be the same as a radial tear in other locations.

However, posterior root tears of the lateral meniscus can be difficult to diagnose because of the oblique orientation of the root to coronal and sagittal images, prominent signal due to the magic angle effect, and arterial pulsation from the popliteal artery partially obscuring the root. Despite these limitations, MRI had 93% sensitivity and 89% sensitivity for diagnosing lateral posterior root tears in a retrospective study [21].

Indirect Signs of a Meniscal Tear

In addition to the presence of a torn posterosuperior fascicle, two other MR findings have a high positive predictive value for a meniscal tear: subchondral edema beneath a meniscus and the presence of a parameniscal cyst. If either of these findings is noted, the overlying meniscus should be carefully evaluated on MRI for a tear.

Subchondral Bone Marrow Edema Beneath a Meniscus

The most common cause of a focal subchondral area of high signal intensity on T2-weighted MRI of the knee is reactive edema beneath an area of cartilage degeneration. However, after an episode of acute trauma, a subchondral area of high T2 signal intensity is often caused by acute hemorrhage and is termed a "bone bruise." Biopsies of bone bruises have identified hemorrhage and trabecular fractures [51].

In one study of 70 patients who underwent knee MRI and arthroscopy, a focus of tibial subchondral edema beneath a meniscus had a 92–100% positive predictive value for an overlying meniscal tear [52]. In another study, a bone bruise in the posterior margin of the medial tibial plateau had a positive predictive value of 64% for the presence of a peripheral posterior horn medial meniscal tear [53] (Fig. 25).

Presence of a Parameniscal Cyst

There are many causes of fluid-filled structures around the knee including cruciate ganglia, synovial cysts, bursitis, and parameniscal cysts [54]. On T2-weighted imaging, a parameniscal cyst is a high-signal-intensity fluid collection either directly overlying a meniscus or adjacent to a meniscus with a fluid track connecting to the periphery of a meniscus (Fig. 22B).

There is a strong association between the presence of a parameniscal cyst and an underlying meniscal tear. The reported association between parameniscal cysts and meniscal tears has ranged from 90% to 100% in MRI series [55]. The only exception to this high association is at the anterior horn of the lateral meniscus [55] where an underlying meniscal tear was found in only 64% of patients with these cysts.

Nuances in the MR Diagnosis of Meniscal Tear

Although the criteria for MR diagnosis of a meniscal tear are well established, there are nuances that can be used to improve the diagnostic accuracy of interpretation. In early reports on the MR appearance of the meniscus, investigators noted that menisci often have prominent internal signal. However, unless this internal signal contacted an articular surface of the meniscus, a meniscal tear was seldom found at surgery [56]. If one is uncertain whether the signal contacts the articular surface of a meniscus on MRI, the meniscus should be diagnosed as intact because a tear is infrequent and is no more likely than when the signal does not contact the surface [1, 57].

Two-Slice-Touch Rule

As an extension of these two studies [56], investigators first noted in 1993 [1] and confirmed in 2006 [58] and 2009 [59] that if intrameniscal signal contacted the surface of the meniscus on only one MR image, there was only an 18–55% likelihood that a tear of the meniscus would be found at arthroscopy. In contrast, if there was surface contact on two or more images, there was a 90–96% likelihood that a meniscal tear would be identified at that location on subsequent knee arthroscopy [1, 58]. The signal to the surface must be in the same area of the meniscus on the two images, but one image can be in the coronal plane and one, in the sagittal plane. This observation has been referred to as the "two-slice-touch rule" [58].

Meniscal Fraying

Because the resolution of knee MRI has improved, it is possible to diagnose tears of the meniscus that are only several millimeters long. This improved resolution also allows MR visualization of fraying of a meniscus (Fig. 26). In some patients, significant fraying of the meniscus may be clinically significant and may be treated by resection as representing free-edge tearing. However, in most patients these minor meniscal changes are unlikely to be symptomatic and the meniscus may be described by the surgeon as intact at arthroscopy. Thus the fraying noted on MRI may or may not be described in an arthroscopic report as representing a meniscal tear depending on the extent of fraying and the patient's symptoms.

Studies on the MR accuracy of diagnosing meniscal tears have noted that apparent false-positive and false-negative MR diagnoses of

Downloaded from ajronline.org by 2800:2331:7300:162:cd27:c8e:3456:2d47 on 11/22/26 from IP address 2800:2331:7300:162:cd27:c8e:3456:2d47. Copyright ARRS. For personal use only; all rights reserved

meniscal tears may reflect these variations in arthroscopists' terminology of the type of meniscal abnormality [60, 61]. In my experience, the MR appearance of small meniscal tears and of fraying differs from that of a typical meniscal tear. In most patients, meniscal signal to the surface on MRI of a frayed meniscus will be present on only one MR image, which I would diagnose as a possible tear and not as a definite tear.

In other patients, MRI may indicate a meniscal abnormality but the appearance of the abnormality is different from that of a definite meniscal tear. When MR images show signal to the surface but with a horizontal signal orientation or only ill definition of the free edge of the meniscus, I indicate in my report that the patient's meniscus may have either a small free-edge tear or fraying (Fig. 26). This type of fraying is most common on the free edge of the body of the lateral meniscus but occasionally causes MR signal abnormalities in other areas of both menisci. When the MR report has a differential diagnosis rather than a specific diagnosis of a tear, the treating physician can discuss conservative management with a patient who may otherwise expect surgery when there is a definite MR diagnosis of a meniscal tear.

In addition to the difficulty of differentiating a meniscal tear from fraying of the free edge of the meniscus, the posterior horn of the lateral meniscus often has diffuse increased signal that can be caused by fraying, synovitis, or a tear (Fig. 27). With this MR appearance and when the patient is younger than 30 years old, has an acute knee injury, or has an associated ACL tear, I interpret the diffuse lateral root signal as indicating a probable posterior root tear. However, when a patient is more than 40 years old, does not have an acute injury, or has adjacent tibial articular cartilage degeneration, I indicate that synovitis or fraying is more likely than a tear when there is increased MR signal in the lateral posterior root.

Uncommonly, the anterior root of the lateral meniscus can have a similar diffuse increased signal that contacts the meniscal articular surface and may be either fraying or a meniscal tear (Fig. 28).

Spontaneous Healing of Tears

Stable peripheral longitudinal tears that were not treated surgically have been found to have healed spontaneously at the time of a second knee arthroscopy [62]. Spontaneous healing of peripheral longitudinal tears is one of the causes for a false-positive MR diagnosis of a meniscal tear [63]. Recently with the higher signal-to-noise ratio available on later-generation MR magnets and with the use of eight-channel phased-array coils, I have modified my MR diagnoses of longitudinal tears on the basis of the appearance of the tear on T2-weighted images.

If a tear has a fluid cleft extending into the surface of the meniscus on two or more T2 images, I diagnose this finding as a definite tear while realizing that the tear may heal by the time of arthroscopy. However, if there is contact of intrameniscal signal with the meniscal surface on proton density–weighted images but not on T2-weighted images, I diagnose this finding as a partially healed tear (Fig. 29). Most longitudinal tears without T2 signal to the meniscal surface will be found to be stable or completely healed at subsequent arthroscopy.

Summary

MRI is a highly accurate imaging method for diagnosing meniscal tears. To avoid errors in diagnosing meniscal tears, those interpreting MR examinations of the knee need to be aware of the attachments of the menisci and the normal variations in meniscal anatomy that may resemble a meniscal tear. In addition, by being aware of the patterns of meniscal tears, it is easier to diagnose the less common tears. In my recent experience, a definitive diagnosis of an intact or a torn meniscus can be made in 95% of knee MR examinations. In the remaining 5% of patients, it is not possible to be definitive but a diagnosis of a possible tear or a probable lateral posterior root tear or a differential diagnosis of meniscal fraying or tear should be given.

References

1. De Smet AA, Norris MA, Yandow DR, Quintana FA, Graf BK, Keene JS. MR diagnosis of meniscal tears of the knee: importance of high signal in the meniscus that extends to the surface. *AJR* 1993; 161:101–107
2. Magee T, Williams D. Detection of meniscal tears and marrow lesions using coronal MRI. *AJR* 2004; 183:1469–1473
3. Stoller DW, Martin C, Crues JV 3rd, Kaplan L, Mink JH. Meniscal tears: pathologic correlation with MR imaging. *Radiology* 1987; 163:731–735
4. Takeda Y, Ikata T, Yoshida S, Takai H, Kashiwaguchi S. MRI high-signal intensity in the menisci of asymptomatic children. *J Bone Joint Surg Br* 1998; 80:463–467
5. Cothran RL, Major NM, Helms CA, Higgins LD. MR imaging of meniscal contusion in the knee. *AJR* 2001; 177:1189–1192
6. Metcalf MH, Barrett GR. Prospective evaluation of 1485 meniscal tear patterns in patients with stable knees. *Am J Sports Med* 2004; 32:675–680
7. Manaster BJ. Magnetic resonance imaging of the knee. *Semin Ultrasound CT MR* 1990; 11:307–326
8. Yu JS, Cosgarea AJ, Kaeding CC, Wilson D. Meniscal flounce MR imaging. *Radiology* 1997; 203:513–515
9. Park JS, Ryu KN, Yoon KH. Meniscal flounce on knee MRI: correlation with meniscal locations after positional changes. *AJR* 2006; 187:364–370
10. Wright RW, Boyer DS. Significance of the arthroscopic meniscal flounce sign. *Am J Sports Med* 2007; 35:242–244
11. Berlet GC, Fowler PJ. The anterior horn of the medial meniscus. *Am J Sports Med* 1998; 26:540–543
12. Cha JG, Min KD, Han JK, et al. Anomalous insertion of the medial meniscus into the anterior cruciate ligament: the MR appearance. *Br J Radiol* 2008; 81:20–24
13. Aydıngöz U, Kaya A, Atay A, Oztürk H, Doral N. MR imaging of the anterior intermeniscal ligament: classification according to insertion sites. *Eur Radiol* 2002; 12:824–829
14. Herman LJ, Beltran J. Pitfalls in MR imaging of the knee. *Radiology* 1988; 167:775–781
15. Shankman S, Beltran J, Melamed E, Rosenberg ZS. Anterior horn of the lateral meniscus: another potential pitfall in MR imaging of the knee. *Radiology* 1997; 204:181–184
16. Peduto AJ, Nguyen A, Trudell DJ, Resnick DL. Popliteomeniscal fascicles: anatomic considerations using MR arthrography in cadavers. *AJR* 2008; 190:442–448
17. Johnson RL, De Smet AA. MR visualization of the popliteomeniscal fascicles. *Skeletal Radiol* 1999; 28:561–566
18. Simonian PT, Sussmann PS, Wickiewicz TL, et al. Popliteomeniscal fasciculi and the unstable lateral meniscus: clinical correlation and magnetic resonance diagnosis. *Arthroscopy* 1997; 13:590–596
19. de Abreu M, Chung C, Trudell D, Resnick D. Meniscofemoral ligaments: patterns of tears and pseudotears of the menisci using cadaveric and clinical material. *Skeletal Radiol* 2007; 36:729–735
20. Brody JM, Hulstyn MJ, Fleming BC, Tung GA. The meniscal roots: gross anatomic correlation with 3-T MRI findings. *AJR* 2007; 188:1306; [web] W446–W450
21. De Smet AA, Blankenbaker DG, Kijowski R, Graf BK, Shinki K. MR diagnosis of posterior root tears of the lateral meniscus using arthroscopy as the reference standard. *AJR* 2009; 192:480–486
22. Woods GW, Whelan MJ. Discoid meniscus. *Clin Sports Med* 1990; 9:695–706
23. Araki Y, Yamamoto H, Nakamura H, Tsukaguchi I.

MR diagnosis of discoid lateral menisci of the knee. *Eur J Radiol* 1994; 18:92–95

24. Stark JE, Siegel MJ, Weinberger E, Shaw DWW. Discoid menisci in children: MR features. *J Comput Assist Tomogr* 1995; 19:608–611
25. Ryu KN, Kim IS, Kim EJ, et al. MR imaging of tears of discoid lateral menisci. *AJR* 1998; 171:963–967
26. Kim YG, Ihn JC, Park SK, Kyung HS. An arthroscopic analysis of lateral meniscal variants and a comparison with MRI findings. *Knee Surg Sports Traumatol Arthrosc* 2006; 14:20–26
27. Ginés-Cespedosa A, Monllau JC. Symptomatic ring-shaped medial meniscus. *Clin Anat* 2007; 20:994–995
28. Schnarkowski P, Tirman PF, Fuchigami KD, Crues JV, Butler MG, Genant HK. Meniscal ossicle: radiographic and MR imaging findings. *Radiology* 1995; 196:47–50
29. Sanders TG, Linares RC, Lawhorn KW, Tirman PFJ, Houser C. Oblique meniscomeniscal ligament: another potential pitfall for a meniscal tear—anatomic description and appearance at MR imaging in three cases. *Radiology* 1999; 213:213–216
30. Jee WH, McCauley TR, Kim JM, et al. Meniscal tear configurations: categorization with MR imaging. *AJR* 2003; 180:93–97
31. Dillon EH, Pope CF, Jokl P, Lynch JK. Follow-up of grade 2 meniscal abnormalities in the stable knee. *Radiology* 1991; 181:849–852
32. Munk B, Lundorf E, Jensen J. Long-term outcome of meniscal degeneration in the knee: poor association between MRI and symptoms in 45 patients followed more than 4 years. *Acta Orthop Scand* 2004; 75:89–92
33. Crema MD, Hunter DJ, Roemer FW, et al. The relationship between prevalent medial meniscal intrasubstance signal changes and incident medial meniscal tears in women over a 1-year period assessed with 3.0 T MRI. *Skeletal Radiol* 2011; 40:1017–1023
34. Zanetti M, Pfirrmann CWA, Schmid MR, Romero J, Seifert B, Hodler J. Clinical course of knees with asymptomatic meniscal abnormalities: findings at 2-year follow-up after MR imaging–based diagnosis. *Radiology* 2005; 237:993–997
35. De Smet AA, Graf BK. Meniscal tears missed on MR imaging: relationship to meniscal tear patterns and anterior cruciate ligament tears. *AJR* 1994; 162:905–911
36. Blankenbaker DG, De Smet AA, Smith JD. Usefulness of two indirect MR imaging signs to diagnose lateral meniscal tears. *AJR* 2002; 178:579–582
37. Laundre BJ, Collins MS, Bond JR, Dahm DL, Stuart MJ, Mandrekar JN. MRI accuracy for tears of the posterior horn of the lateral meniscus in patients with acute anterior cruciate ligament injury and the clinical relevance of missed tears. *AJR* 2009; 193:515–523
38. Park L, Jacobson J, Jamadar D, Caoili E, Kalume-Brigido M, Wojtys E. Posterior horn lateral meniscal tears simulating meniscofemoral ligament attachment in the setting of ACL tear: MRI findings. *Skeletal Radiol* 2007; 36:399–403
39. Dorsay TA, Helms CA. Bucket-handle meniscal tears of the knee: sensitivity and specificity of MRI signs. *Skeletal Radiol* 2003; 32:266–272
40. Weiss KL, Morehouse HT, Levy IM. Sagittal MR images of the knee: a low-signal band parallel to the posterior cruciate ligament caused by a displaced bucket-handle tear. *AJR* 1991; 156:117–119
41. Haramati N, Staron RB, Rubin S, Shreck EH, Feldman F, Kiernan H. The flipped meniscus sign. *Skeletal Radiol* 1993; 22:273–277
42. Harper KW, Helms CA, Lambert HS, Higgins LD. Radial meniscal tears: significance, incidence, and MR appearance. *AJR* 2005; 185:1429–1434
43. Lerer DB, Umans HR, Hu MX, Jones MH. The role of meniscal root pathology and radial meniscal tear in medial meniscal extrusion. *Skeletal Radiol* 2004; 33:569–574
44. Bullough PG, Munuera L, Murphy J, Weinstein AM. The strength of the menisci of the knee as it relates to their fine structure. *J Bone Joint Surg Br* 1970; 52:564–567
45. Tarhan NC, Chung CB, Mohana-Borges AV, Hughes T, Resnick D. Meniscal tears: role of axial MRI alone and in combination with other imaging planes. *AJR* 2004; 183:9–15
46. McKnight A, Southgate J, Price A, Ostlere S. Meniscal tears with displaced fragments: common patterns on magnetic resonance imaging. *Skeletal Radiol* 2010; 39:279–283
47. Lecas LK, Helms CA, Kosarek FJ, Garret WE. Inferiorly displaced flap tears of the medial meniscus. *AJR* 2000; 174:161–164
48. Koenig JH, Ranawat AS, Umans HR, DiFelice GS. Meniscal root tears: diagnosis and treatment. *Arthroscopy* 2009; 25:1025–1032
49. Lee Y, Shim J, Choi Y, Kim J, Lee G, Kim H. Magnetic resonance imaging findings of surgically proven medical meniscus root tear: tear configuration and associated knee abnormalities. *J Comput Assist Tomogr* 2008; 32:452–457
50. Lee SY, Jee WH, Kim JM. Radial tear of the medial meniscal root: reliability and accuracy of MRI for diagnosis. *AJR* 2008; 191:81–85
51. Nakamae A, Engebretsen L, Bahr R, Krosshaug T, Ochi M. Natural history of bone bruises after acute knee injury: clinical outcome and histopathological findings. *Knee Surg Sports Traumatol Arthrosc* 2006; 14:1252–1258
52. Bergin D, Hochberg H, Zoga AC, Qazi N, Parker L, Morrison WB. Indirect soft-tissue and osseous signs on knee MRI of surgically proven meniscal tears. *AJR* 2008; 191:86–92
53. Kaplan PA, Gehl RH, Dussault RG, Anderson MW, Diduch DR. Bone contusions of the posterior lip of the medial tibial plateau (contrecoup injury) and associated internal derangements of the knee at MR imaging. *Radiology* 1999; 211:747–753
54. Janzen DL, Peterfy CG, Forbes JR, Tirman PF, Genant HK. Cystic lesions around the knee joint: MR imaging findings. *AJR* 1994; 163:155–161
55. De Smet AA, Graf BK, del Rio AM. Association of parameniscal cysts with underlying meniscal tears as identified on MRI and arthroscopy. *AJR* 2011; 196:430; [web]W180–W186
56. Crues JV, Mink J, Levy TL, Lotysch M, Stoller DW. Meniscal tears of the knee: accuracy of MR imaging. *Radiology* 1987; 164:445–448
57. Kaplan PA, Nelson NL, Garvin KL, Brown DE. MR of the knee: the significance of high signal in the meniscus that does not clearly extend to the surface. *AJR* 1991; 156:333–336
58. De Smet AA, Tuite MJ. Use of the "two-slice-touch" rule for the MRI diagnosis of meniscal tears. *AJR* 2006; 187:911–914
59. Grossman JW, De Smet AA, Shinki K. Comparison of the accuracy rates of 3-T and 1.5-T MRI of the knee in the diagnosis of meniscal tear. *AJR* 2009; 193:509–514
60. Justice W, Quinn S. Error patterns in the MR imaging evaluation of menisci of the knee. *Radiology* 1995; 196:617–621
61. Van Dyck P, Gielen J, D'Anvers J, et al. MR diagnosis of meniscal tears of the knee: analysis of error patterns. *Arch Orthop Trauma Surg* 2007; 127:849–854
62. Weiss C, Lundberg R, Hamberg P, Haven KD, Gillquist J. Non-operative treatment of meniscal tears. *J Bone Joint Surg Am* 1989; 71:811–822
63. De Smet AA, Nathan DH, Graf BK, Haaland BA, Fine JP. Clinical and MRI findings associated with false-positive knee MR diagnoses of medial meniscal tears. *AJR* 2008; 191:93–99

Downloaded from ajronline.org by 2800:2331:7300:162:cd27:c8e:3456:2d47 on 11/22/26 from IP address 2800:2331:7300:162:cd27:c8e:3456:2d47. Copyright ARRS. For personal use only; all rights reserved

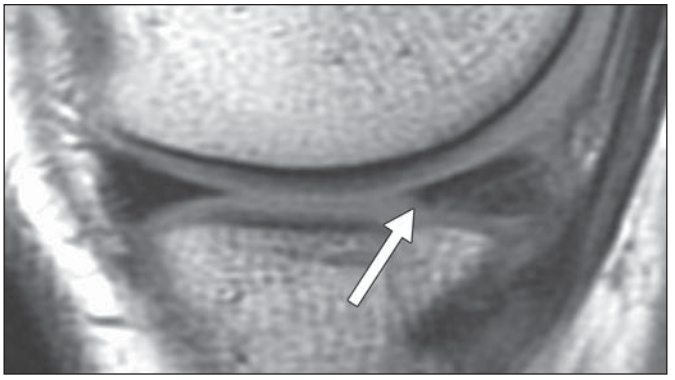

A

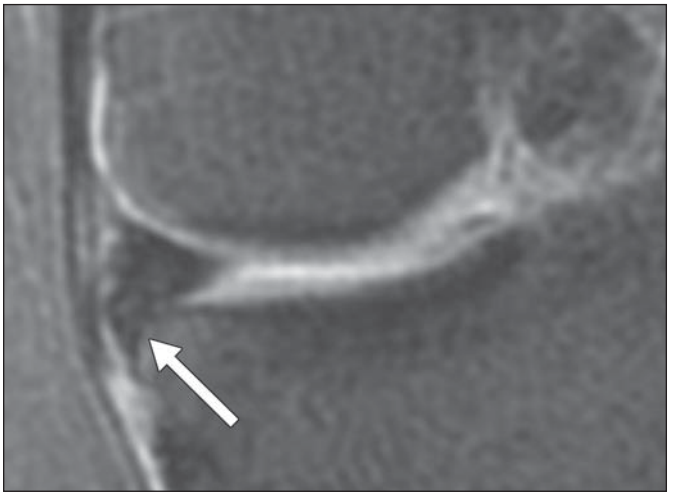

B

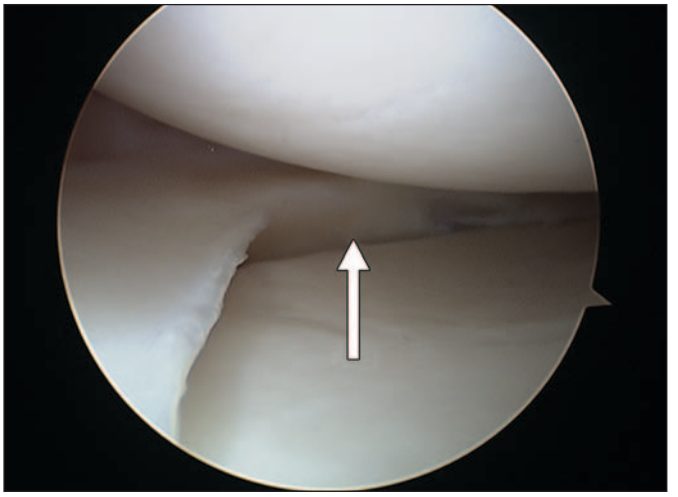

C

Fig. 1—45-year-old man with displaced flap tear of medial meniscus.
A, Sagittal proton density–weighted MR image shows irregularity of meniscal undersurface (*arrow*).
B, Coronal fat-suppressed proton density–weighted image shows displaced fragment in inferior recess beneath body of meniscus (*arrow*).
C, Arthroscopic photograph shows inferior flap (*arrow*).

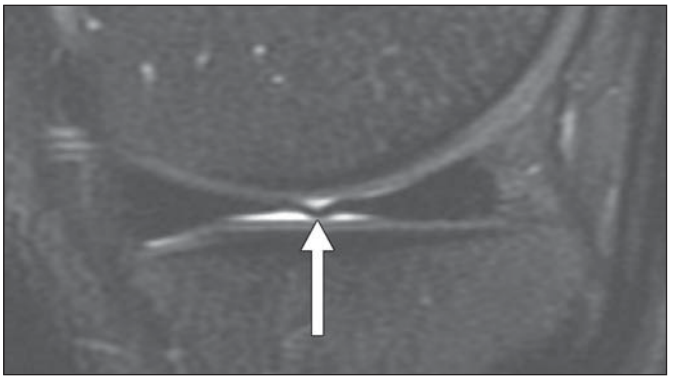

Fig. 2—18-year-old man with normal medial meniscal flounce (*arrow*) on sagittal T2 image.

Downloaded from ajronline.org by 2800:2331:7300:162:cd27:c8e:3456:2d47 on 11/22/26 from IP address 2800:2331:7300:162:cd27:c8e:3456:2d47. Copyright ARRS. For personal use only; all rights reserved

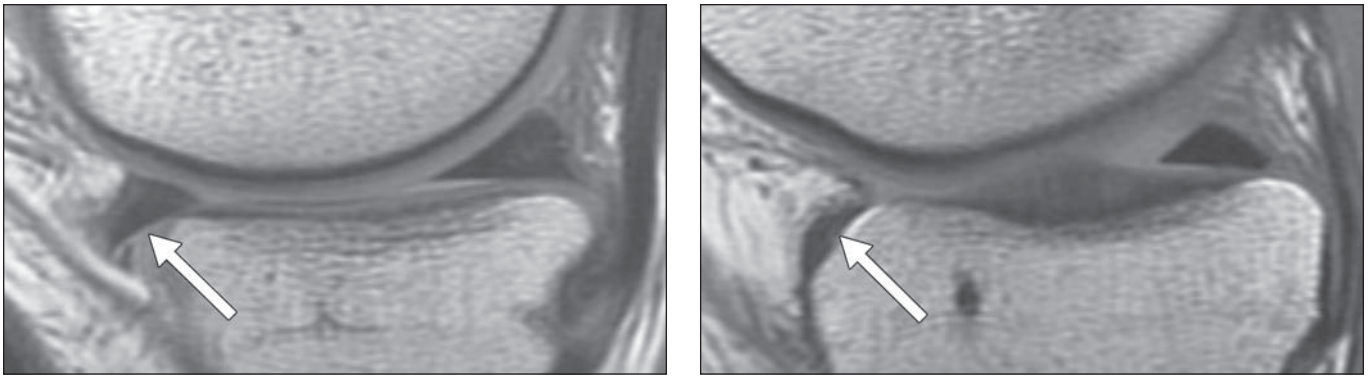

Fig. 3—22-year-old woman with normal apparent anterior subluxation of medial meniscus.
A, Sagittal proton density–weighted image shows anterior horn apparently displaced anterior to anterior margin of tibia (*arrow*).
B, Sagittal proton density–weighted image more medial than **A** shows anterior root attaches on anterior surface of tibia (*arrow*) as normal variation.

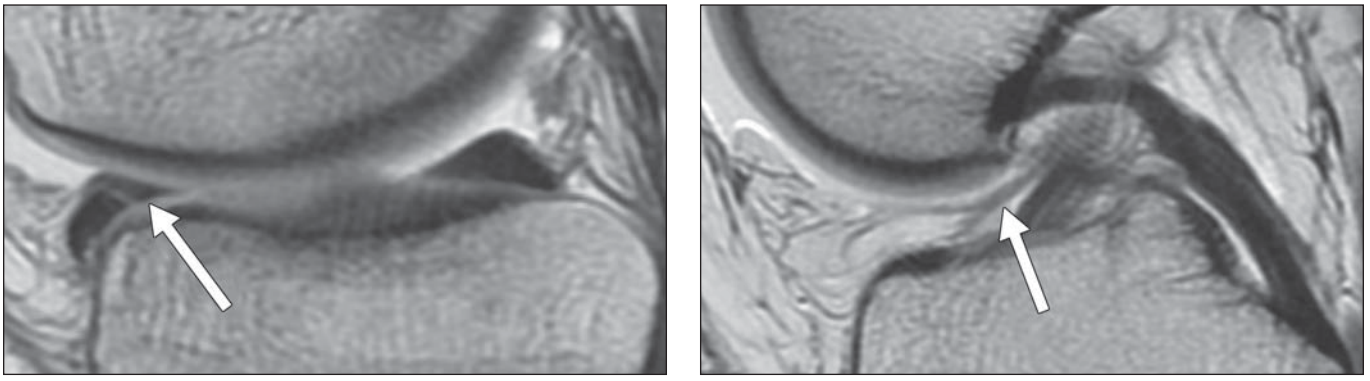

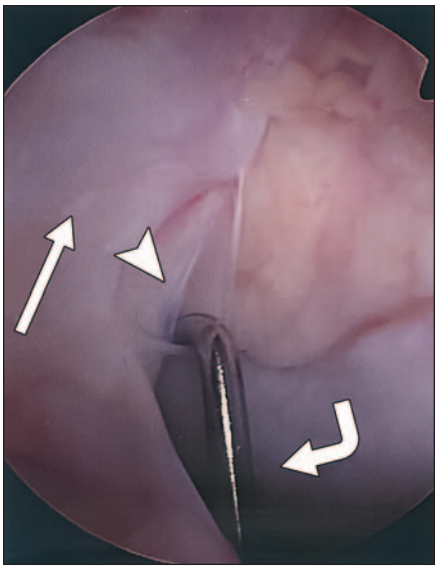

Fig. 4—18-year-old man with variant accessory insertion of medial meniscus onto anterior cruciate ligament (ACL).
A and **B,** Sagittal proton density–weighted images show fibrous strand (*arrows*) arising from anterior horn (**A**) and extending to attach to ACL.
C, Intraoperative photograph shows synovial covered band (*arrowhead*) extending from medial meniscus (*curved arrow*). Note also ACL (*straight arrow*) and split portion of medial meniscal ACL ligament beneath probe tip.

Downloaded from ajronline.org by 2800:2331:7300:162:cd27:c8e:3456:2d47 on 11/22/26 from IP address 2800:2331:7300:162:cd27:c8e:3456:2d47. Copyright ARRS. For personal use only; all rights reserved

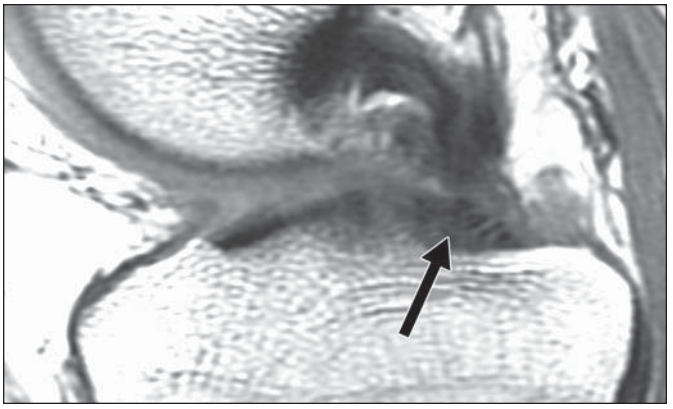

Fig. 5—19-year-old woman with normal medial meniscal root. Sagittal proton density–weighted image shows meniscus flattened at attachment with normal fissured appearance (*arrow*).

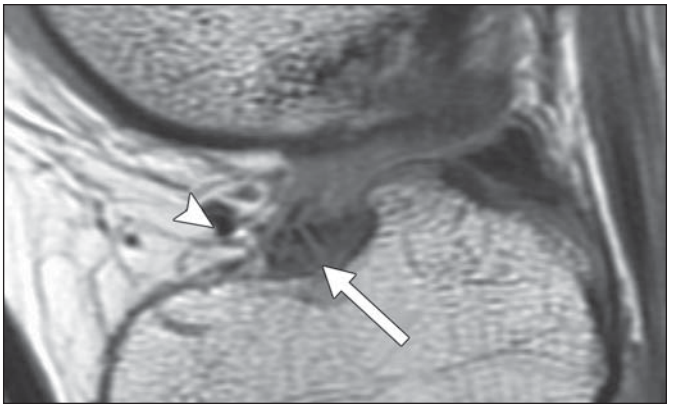

Fig. 6—28-year-old woman with normal lateral meniscus. Midline sagittal proton density–weighted MR image shows transverse meniscal ligament (*arrowhead*) and normal fissured anterior root (*arrow*).

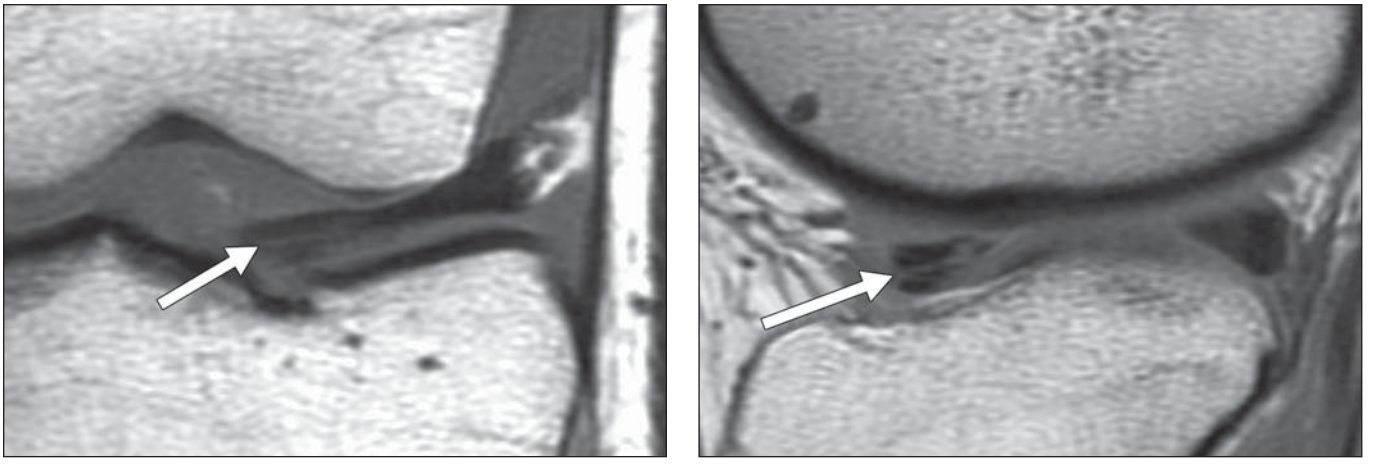

A **B**

Fig. 7—40-year-old woman with normal variant horizontal division of anterior horn of lateral meniscus.
A and **B,** Coronal (**A**) and sagittal (**B**) proton density–weighted images show normal variant (*arrows*).

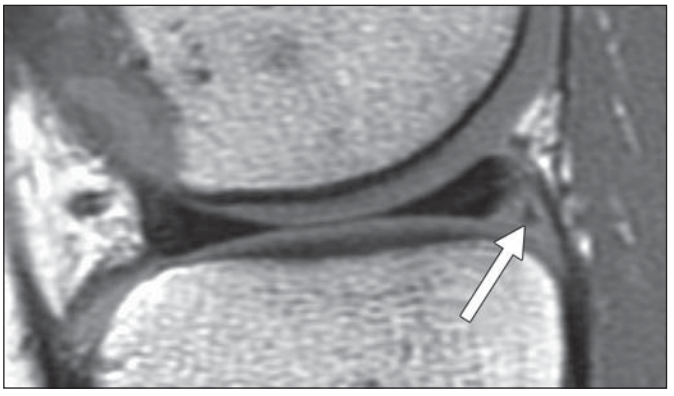

Fig. 8—69-year-old woman with intact lateral meniscus. Normal posteroinferior fascicle (*arrow*) resembles meniscal fragment.

Downloaded from ajronline.org by 2800:2331:7300:162:cd27:c8e:3456:2d47 on 11/22/26 from IP address 2800:2331:7300:162:cd27:c8e:3456:2d47. Copyright ARRS. For personal use only; all rights reserved

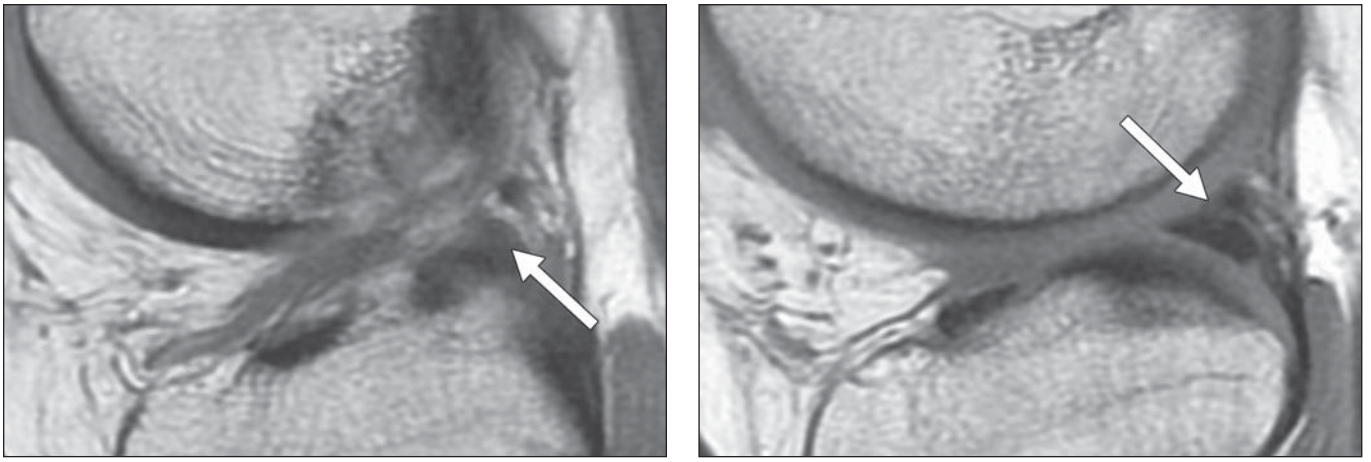

Fig. 9—27-year-old woman with normal meniscofemoral ligaments on sagittal proton density–weighted images.
A, Apparent distortion of superior surface of lateral meniscus as Humphry ligament attaches to meniscus (*arrow*).
B, As Wrisberg ligament attaches to meniscus, there is apparent cleft on superior surface of meniscus (*arrow*).

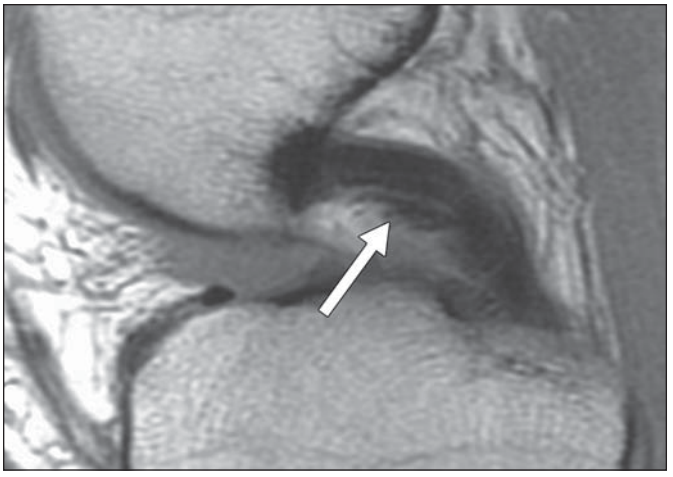

Fig. 10—37-year-old man with prominent Humphry ligament (*arrow*) as it approaches its femoral attachment. Ligament can be distinguished from displaced meniscal fragment by its course on sequential sagittal images.

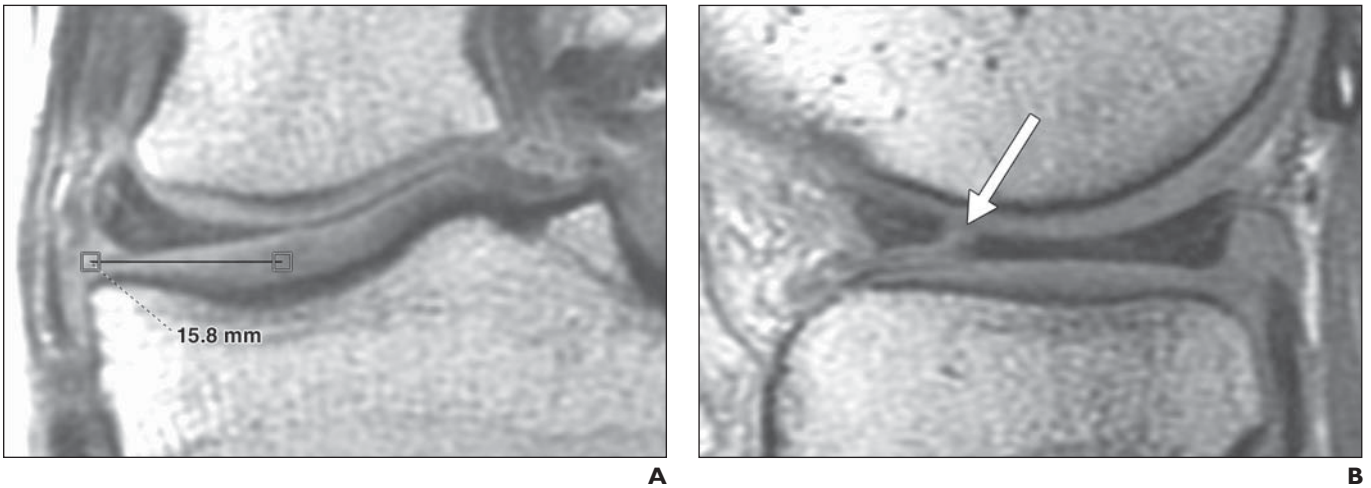

Fig. 11—15-year-old girl with radial tear of anterior horn of incomplete discoid lateral meniscus.
A, Coronal proton density–weighted image shows that meniscus is more than 14 mm in width in midline of knee.
B, Sagittal proton density–weighted image shows radial tear of anterior horn (*arrow*).

Downloaded from ajronline.org by 2800:2331:7300:162:cd27:c8e:3456:2d47 on 11/22/26 from IP address 2800:2331:7300:162:cd27:c8e:3456:2d47. Copyright ARRS. For personal use only; all rights reserved

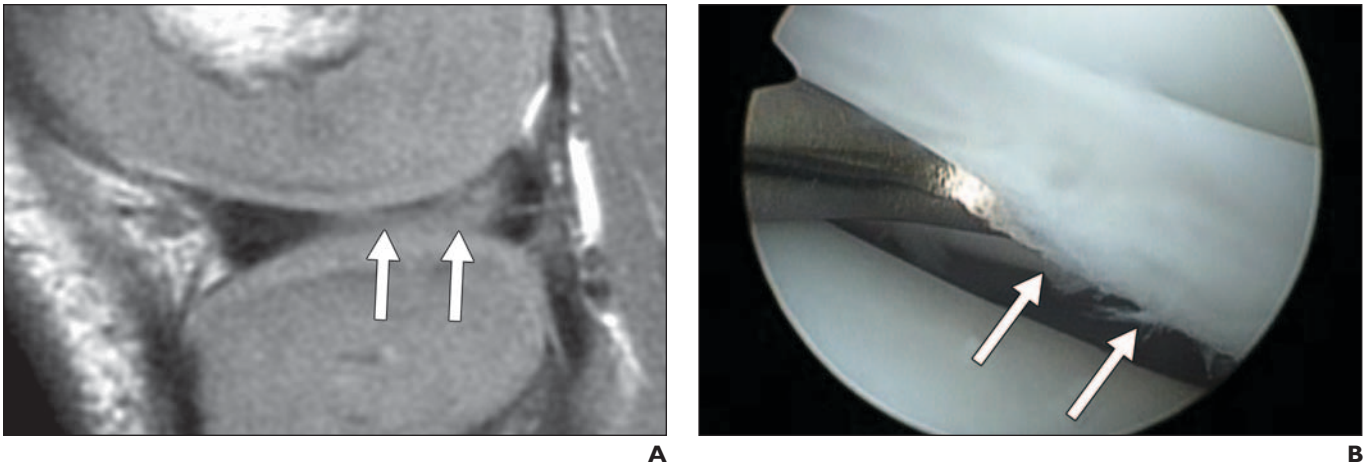

Fig. 12—5-year-old boy with incomplete discoid lateral meniscus.
A, Sagittal proton density–weighted image shows extensive signal to inferior surface (*arrows*).
B, Arthroscopic photograph shows no meniscal tear but reveals fraying (*arrows*) of inferior surface.

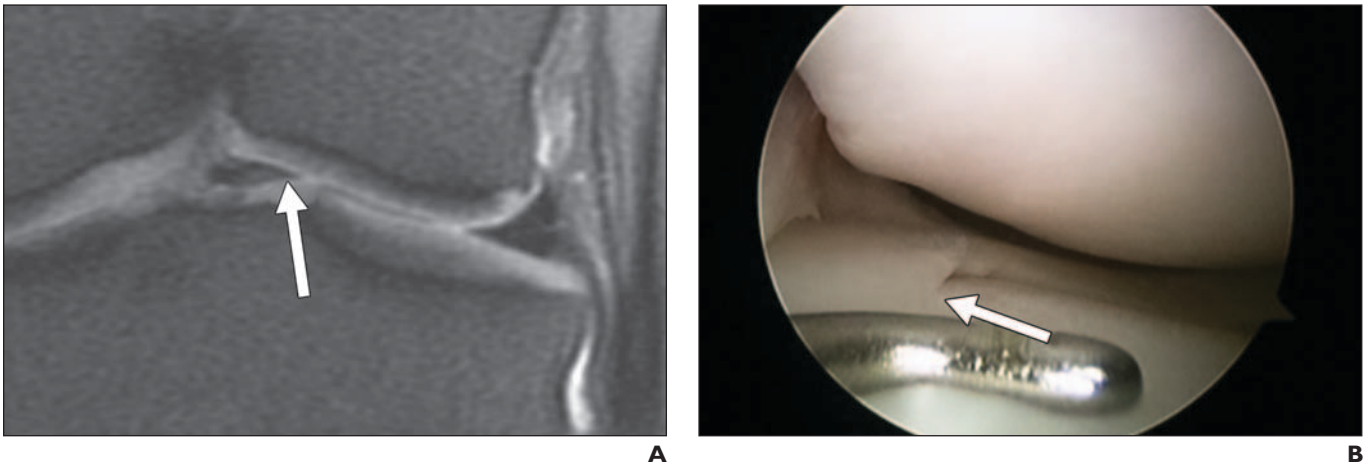

Fig. 13—19-year-old woman with intact ring lateral meniscus.
A, Midline coronal fat-suppressed proton density–weighted image shows triangular appearance of inner aspect of ring meniscus (*arrow*) similar in configuration to body of meniscus.
B, Arthroscopic photograph shows intact inner portion of ring meniscus (*arrow*) within central portion of joint.

Downloaded from ajronline.org by 2800:2331:7300:162:cd27:c8e:3456:2d47 on 11/22/26 from IP address 2800:2331:7300:162:cd27:c8e:3456:2d47. Copyright ARRS. For personal use only; all rights reserved

Downloaded from ajronline.org by 2800:2331:7300:162:cd27:c8e:3456:2d47 on 11/22/26 from IP address 2800:2331:7300:162:cd27:c8e:3456:2d47. Copyright ARRS. For personal use only; all rights reserved

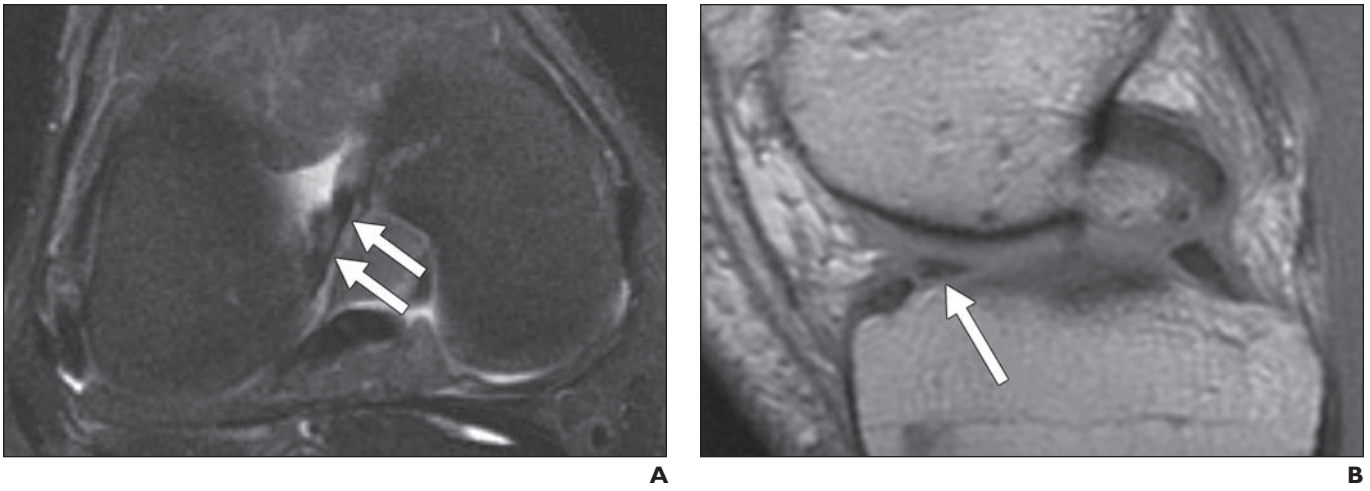

A B

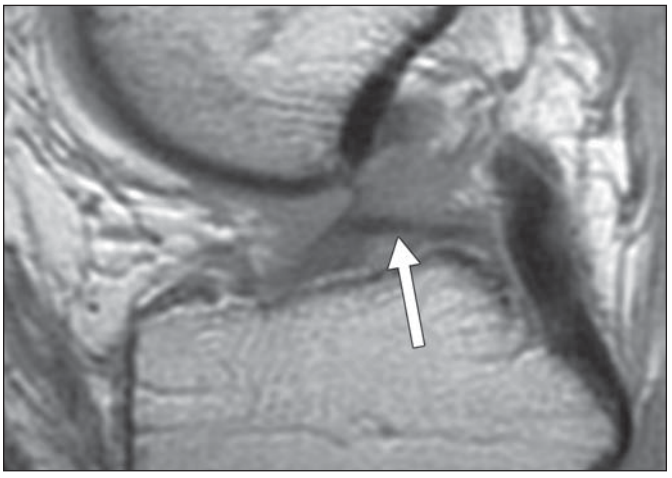

C

Fig. 14—57-year-old man with medial meniscomeniscal ligament.
A, Axial fat-suppressed T2 image shows ligament (*arrows*) passing from anterior horn of medial meniscus to posterior horn of lateral meniscus.
B and **C,** Sagittal proton density–weighted images show ligament adjacent to anterior horn of medial meniscus (*arrow*, **B**) resembling meniscal fragment and ligament at its posterior horn lateral meniscal attachment (*arrow*, **C**).

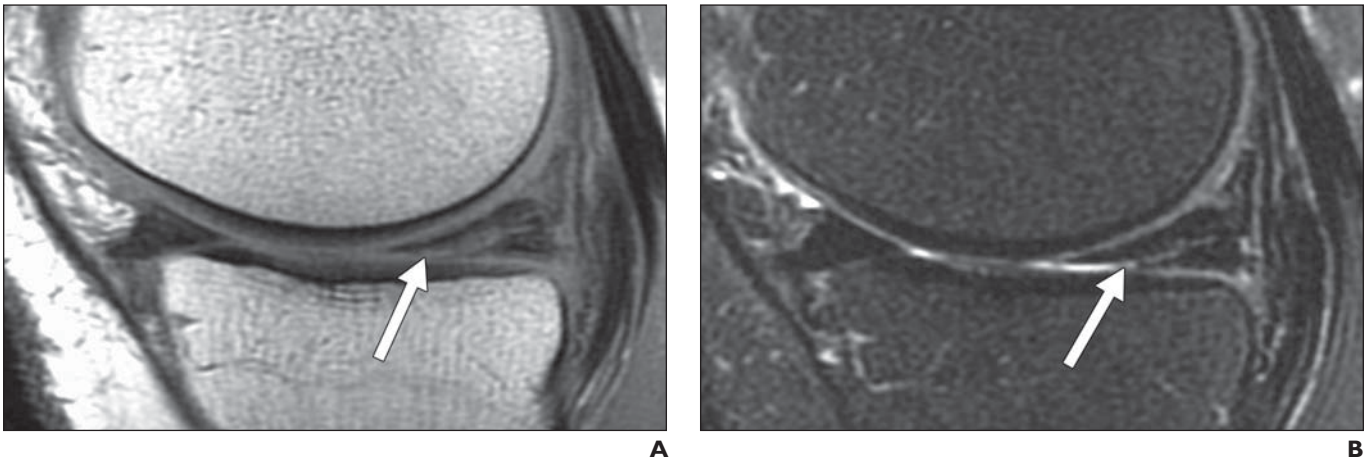

A B

Fig. 15—67-year-old man with posterior horn medial meniscal tear.
A, Sagittal proton density–weighted image shows linear internal meniscal signal likely contacting meniscal surface (*arrow*).
B, Sagittal T2 image confirms that fluid extends from joint into meniscus (*arrow*).

(Fig. 15 continues on next page)

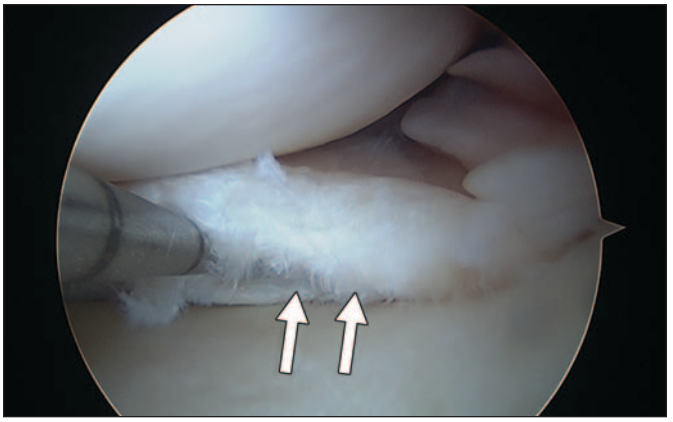

C

Fig. 15 (continued)—67-year-old man with posterior horn medial meniscal tear. **C,** Arthroscopic photograph shows probe within horizontal tear (*arrows*) with prominent fibrillation of superficial surface of tear.

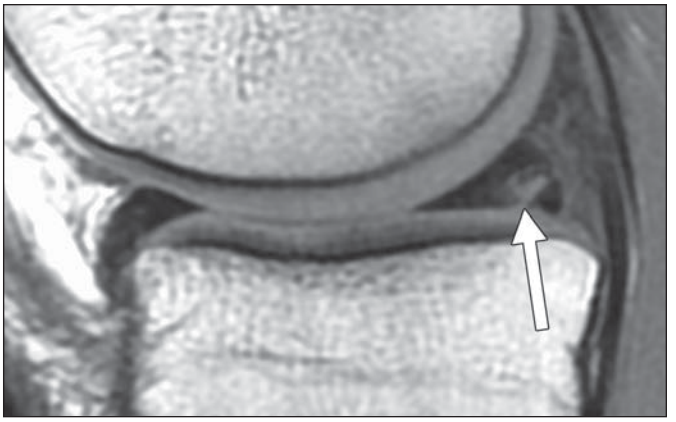

Fig. 16—34-year-old man with longitudinal tear (*arrow*). Sagittal proton density–weighted image shows that tear extends to inferior surface of menisci.

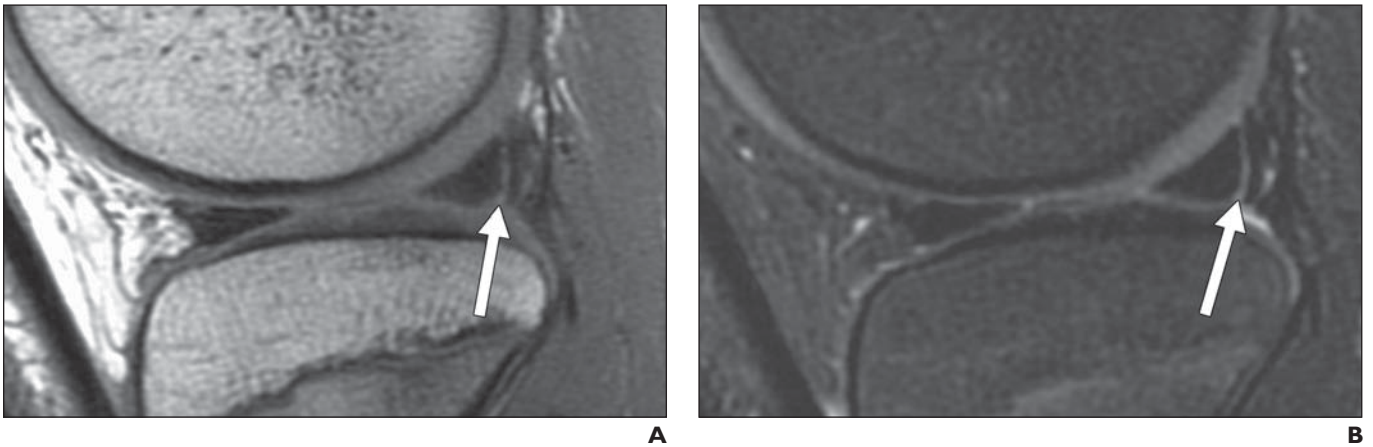

A B

Fig. 17—14-year-old-boy with full-thickness peripheral longitudinal tear of posterior horn of lateral meniscus.
A and **B,** Tear (*arrows*) is evident on proton density–weighted image (**A**) but is more conspicuous as fluid cleft on T2 image (**B**).

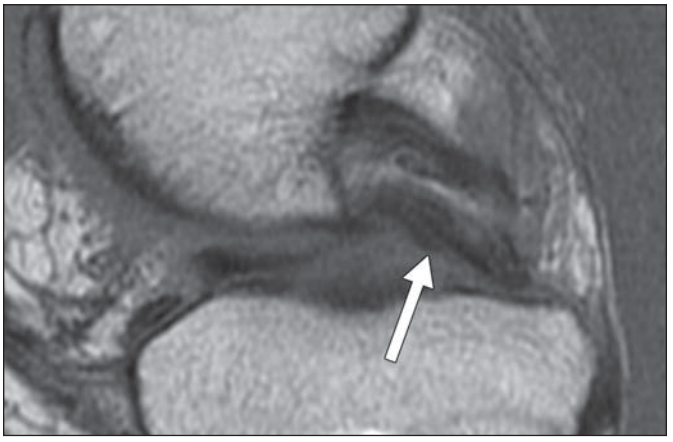

Fig. 18—37-year-old woman with bucket-handle medial meniscal tear. Midline sagittal proton density–weighted image shows displaced central fragment (*arrow*) paralleling posterior cruciate ligament (PCL) creating double PCL sign.



Fig. 19—17-year-old boy with bucket-handle lateral meniscal tear. Sagittal proton density–weighted image shows fragment flipped anteriorly (*arrow*) to abut anterior horn creating flipped meniscus sign.

Downloaded from ajronline.org by 2800:2331:7300:162:cd27:c8e:3456:2d47 on 11/22/26 from IP address 2800:2331:7300:162:cd27:c8e:3456:2d47. Copyright ARRS. For personal use only; all rights reserved

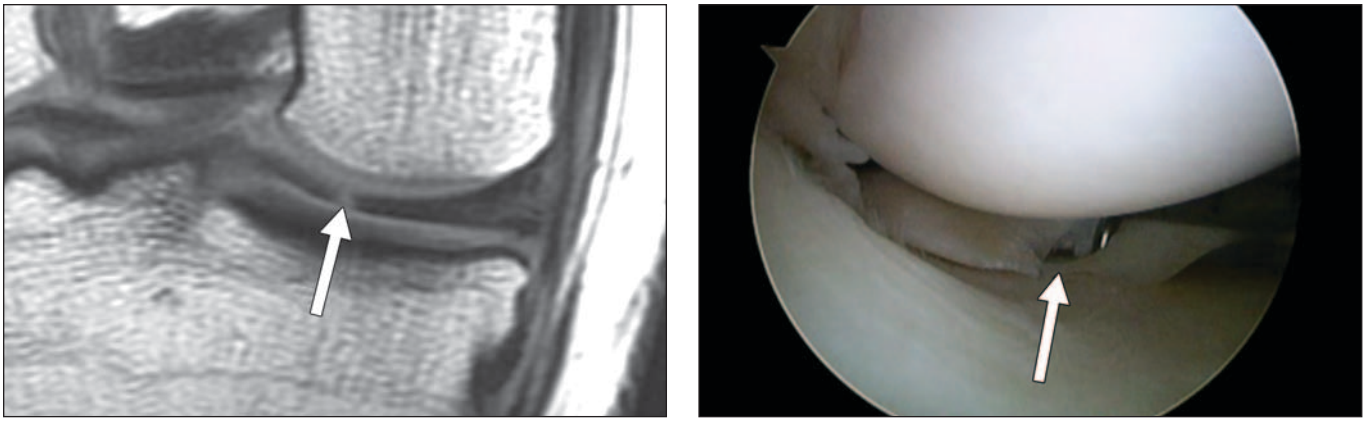

Fig. 20—48-year-old man with radial tear of posterior horn of medial meniscus.
A and **B,** Coronal proton density–weighted images show linear band of increased signal (*arrow*, **A**) corresponding to tear (*arrow*, **B**) seen at arthroscopy.

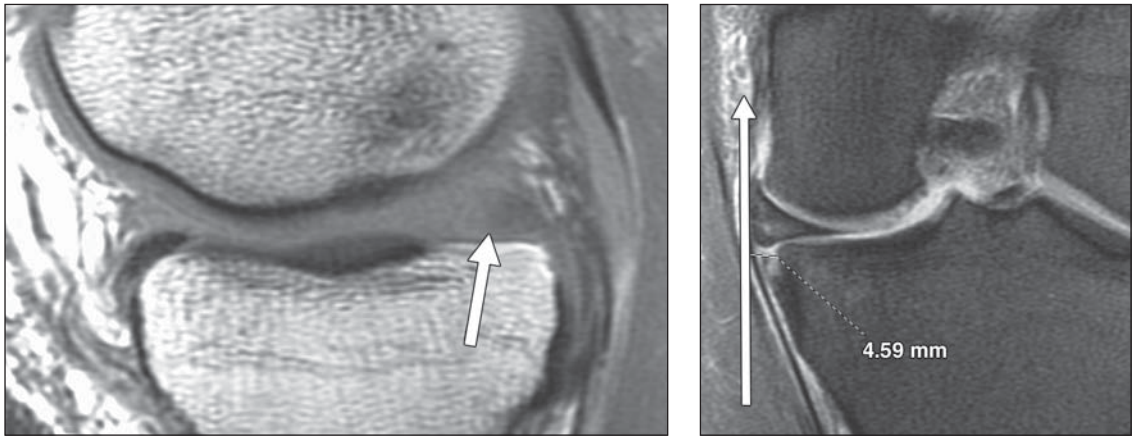

Fig. 21—69-year-old man with radial tear of posterior horn of medial meniscus.
A, Sagittal image shows absent posterior horn (*arrow*), which is called "ghost meniscus" sign.
B, Midline fat-suppressed coronal proton density–weighted image shows medial meniscus (*arrow*) is extruded with displacement of more than 3 mm from edge of tibia.

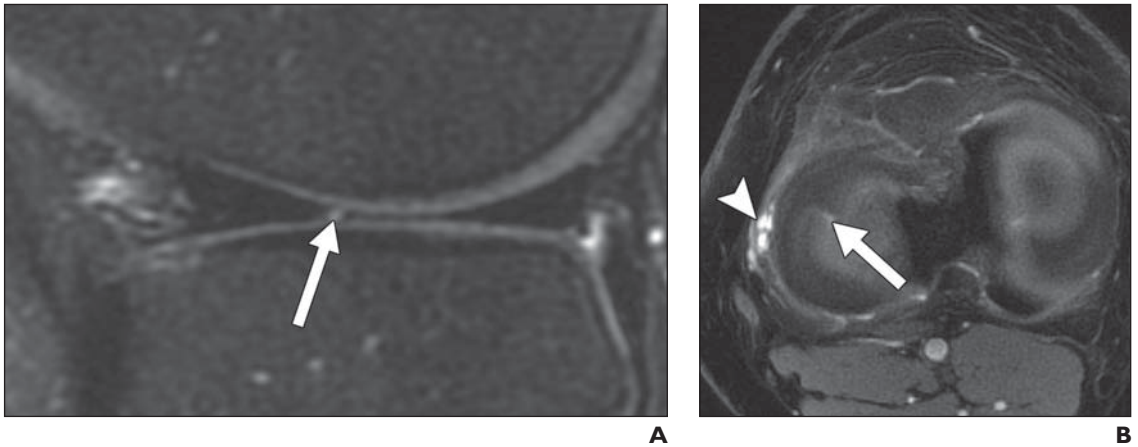

Fig. 22—17-year-old girl with radial tear at junction of body and anterior horn.
A, Sagittal T2 image shows fluid cleft at site of tear (*arrow*). Proton density–weighted image (not shown) had same finding but less conspicuously. Remaining coronal and sagittal images (not shown) showed no other evidence of lateral tear.
B, Axial fat-suppressed gradient-echo image obtained using 0.8-mm slice thickness confirms radial tear (*arrow*) and shows adjacent parameniscal cyst (*arrowhead*).

(Fig. 22 continues on next page)

Downloaded from ajronline.org by 2800:2331:7300:162:cd27:c8e:3456:2d47 on 11/22/26 from IP address 2800:2331:7300:162:cd27:c8e:3456:2d47. Copyright ARRS. For personal use only; all rights reserved

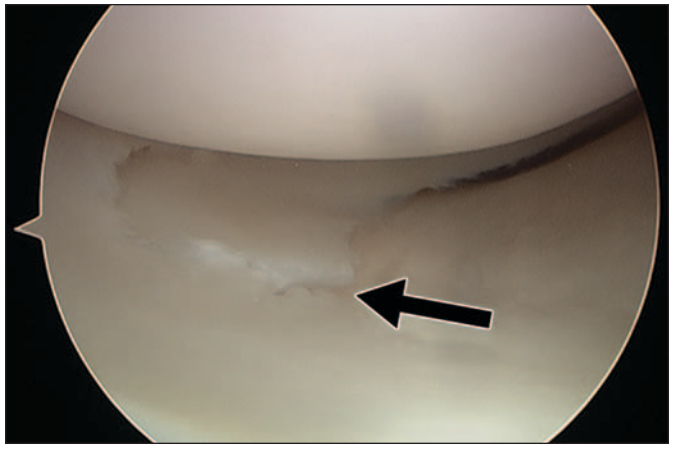

C

Fig. 22 (continued)—17-year-old girl with radial tear at junction of body and anterior horn.
C, Arthroscopic photograph confirms 3-mm-deep radial tear (*arrow*).

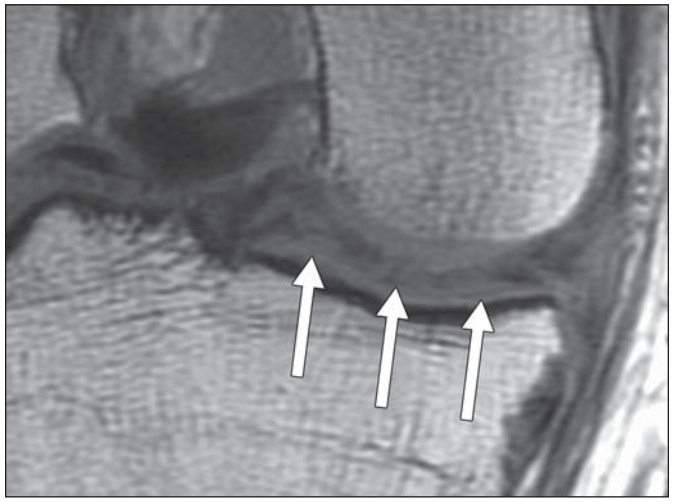

A

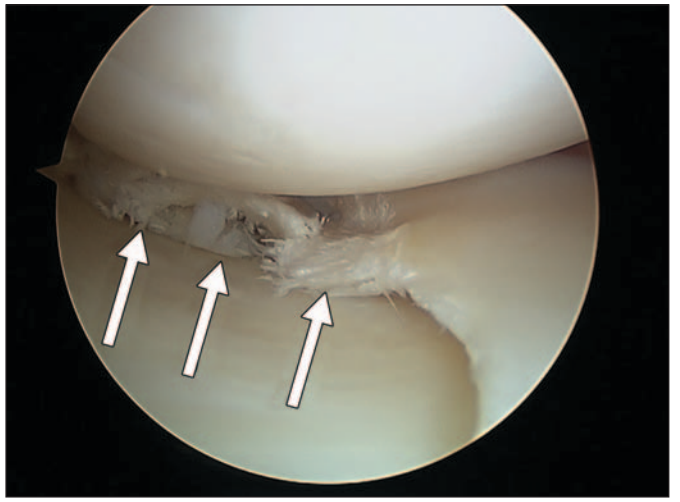

B

Fig. 23—45-year-old man with complex tear of posterior horn of medial meniscus.
A, Coronal proton density–weighted image shows extensive distortion of meniscus (*arrows*).
B, Arthroscopic photograph shows complex pattern of tear (*arrows*).

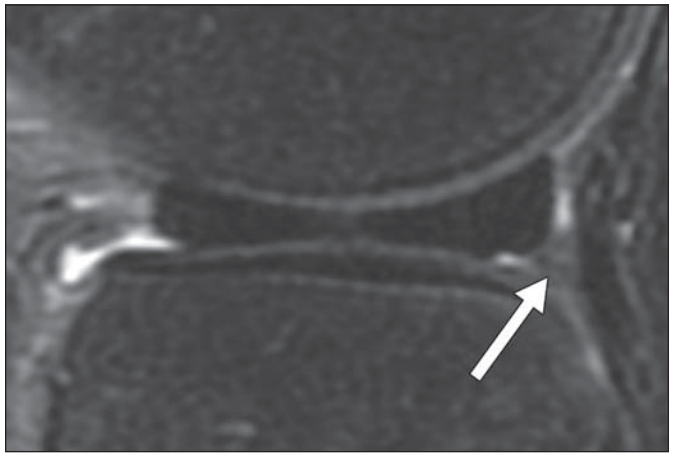

A

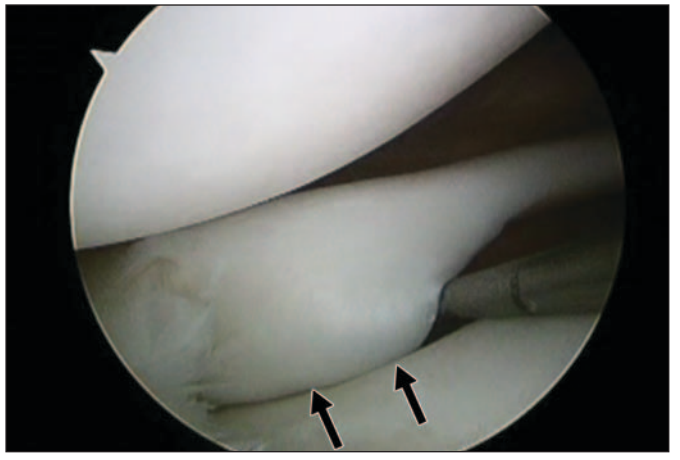

B

Fig. 24—14-year-old boy.
A, Sagittal T2 image shows soft-tissue density (*arrow*) of meniscal flap in popliteus hiatus.
B, Arthroscopic photograph confirms meniscal flap fragment is displaced into popliteus hiatus (*arrows*).

Downloaded from ajronline.org by 2800:2331:7300:162:cd27:c8e:3456:2d47 on 11/22/26 from IP address 2800:2331:7300:162:cd27:c8e:3456:2d47. Copyright ARRS. For personal use only; all rights reserved



Fig. 25—42-year-old man who injured knee 6 weeks earlier. Sagittal T2 image shows peripheral longitudinal tear (*arrow*) of posterior horn of medial meniscus with underlying tibial bone bruise (*arrowhead*).

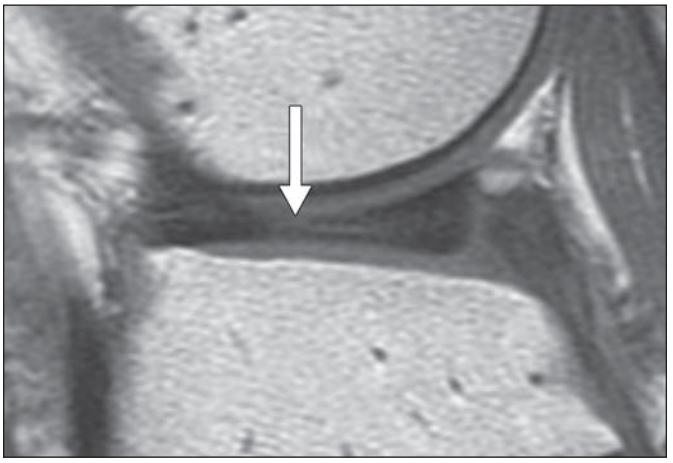

A

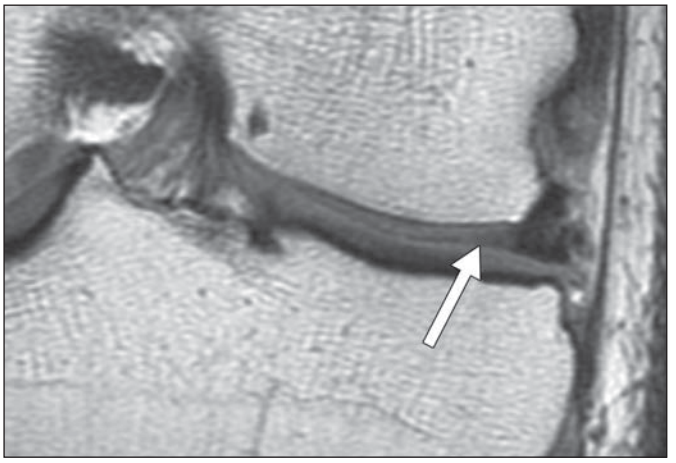

B

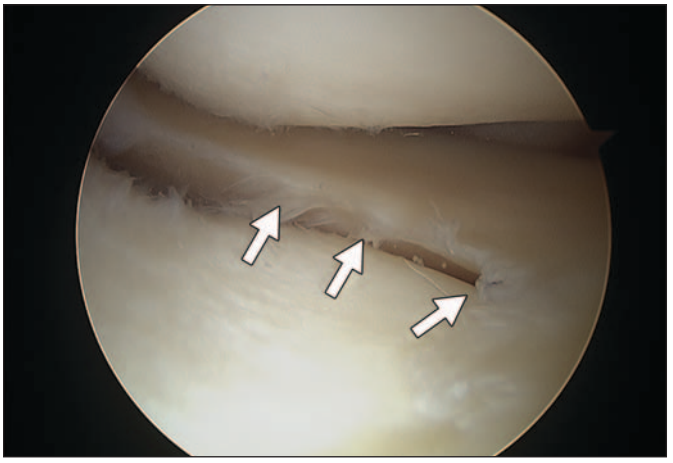

C

Fig. 26—61-year-old man with marked fraying of free edge of body of lateral meniscus.
A and **B,** Sagittal proton density–weighted (**A**) and coronal proton density–weighted (**B**) MR images show signal to surface (*arrow*, **A**) on sagittal proton density–weighted image with ill-defined free edge (*arrow*, **B**) on coronal proton density–weighted image.
C, Arthroscopic photograph shows extensive fraying (*arrows*), but arthroscopist did not consider meniscus as torn.

Downloaded from ajronline.org by 2800:2331:7300:162:cd27:c8e:3456:2d47 on 11/22/26 from IP address 2800:2331:7300:162:cd27:c8e:3456:2d47. Copyright ARRS. For personal use only; all rights reserved

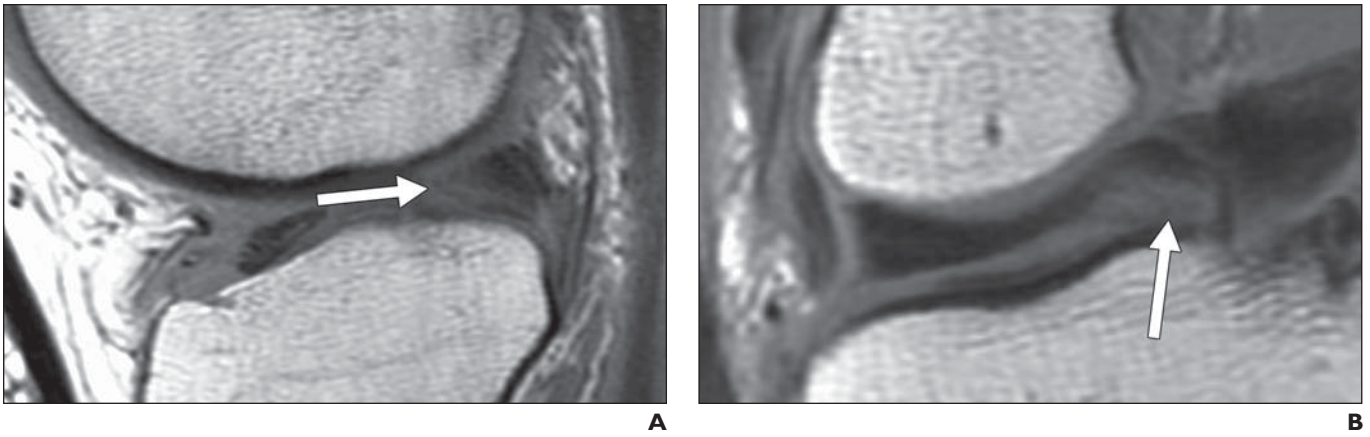

A B

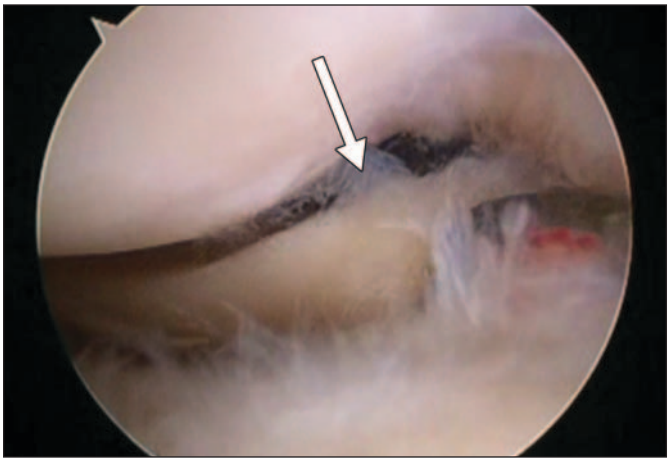

C

Fig. 27—58-year-old woman with fraying and adjacent synovitis of lateral posterior root.
A and **B,** Sagittal (**A**) and coronal (**B**) proton density–weighted images show increased signal contacting surface of root (*arrows*).
C, Arthroscopic photograph shows fraying (*arrow*) of root without tear and underlying cartilage fibrillation and synovitis.

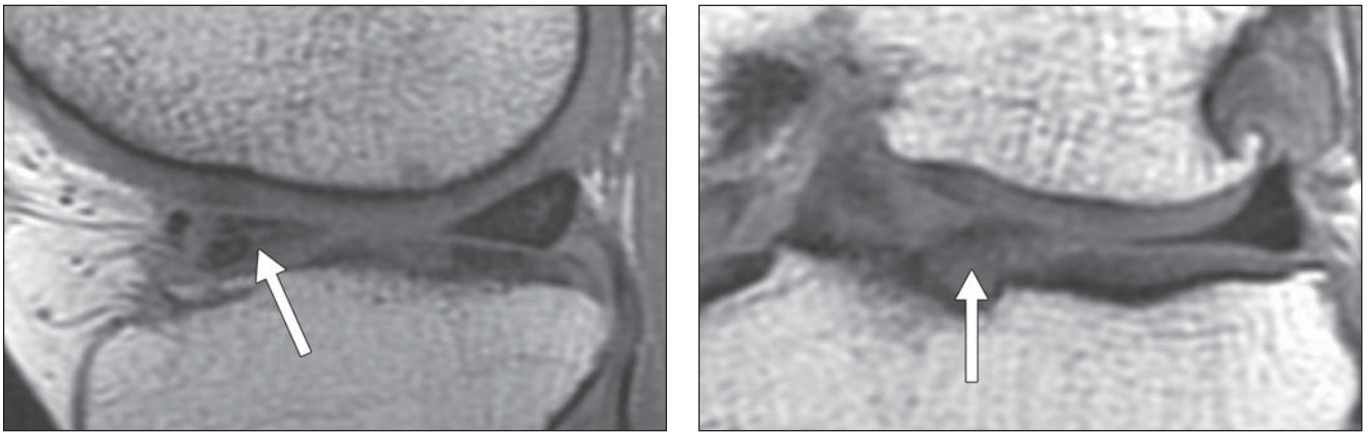

A B

Fig. 28—43-year-old woman with fraying and synovitis surrounding anterior root of lateral meniscus as documented at arthroscopy.
A and **B,** Coronal (**A**) and sagittal (**B**) proton density–weighted images show increased signal at root (*arrows*).

Downloaded from ajronline.org by 2800:2331:7300:162:cd27:c8e:3456:2d47 on 11/22/26 from IP address 2800:2331:7300:162:cd27:c8e:3456:2d47. Copyright ARRS. For personal use only; all rights reserved

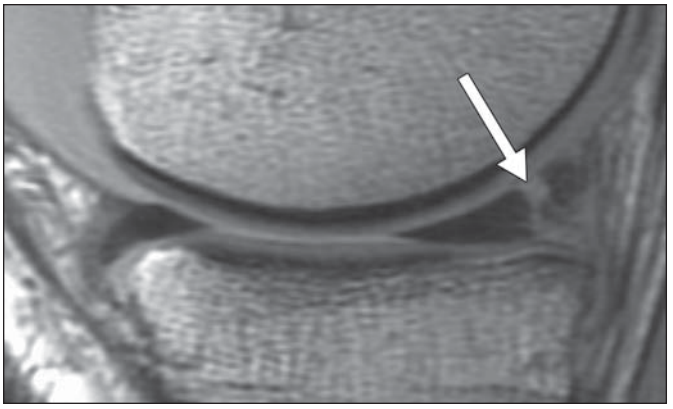

A

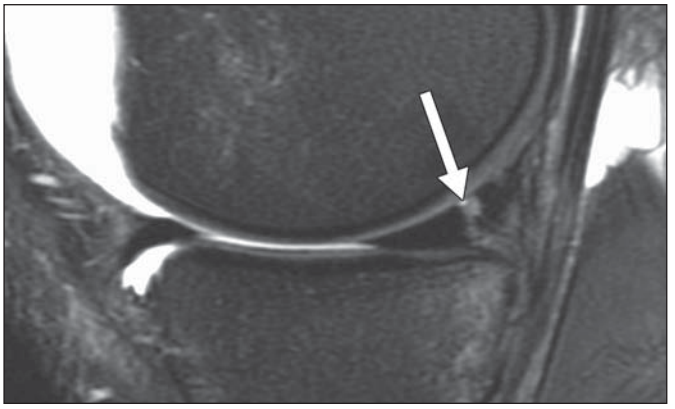

B

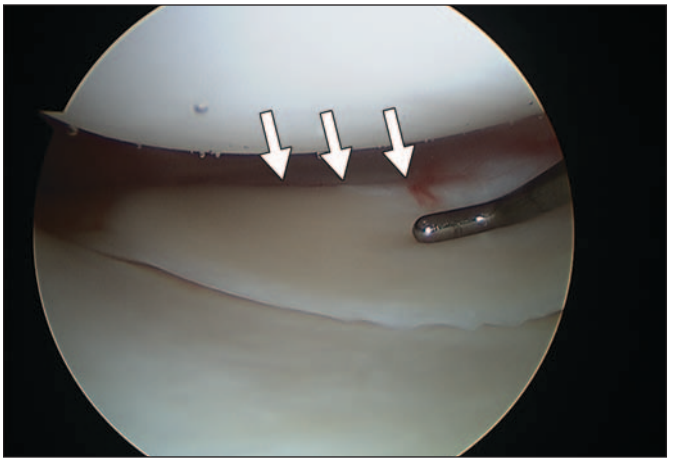

C

Fig. 29—26-year-old man with peripheral longitudinal posterior medial meniscal tear found to be healed at arthroscopy 3 months later.
A, Sagittal proton density–weighted image shows tear (*arrow*) confirmed on five other sagittal images.
B, Sagittal T2 image shows tissue (*arrow*) and not fluid bridging tear site.
C, Arthroscopic photograph obtained 3 months after **A** and **B** shows healed tear (*arrows*).

FOR YOUR INFORMATION

This article is available for CME credit. Log onto www.arrs.org; click on *AJR* (in the blue Publications box); click on the article name; add the article to the cart; proceed through the checkout process.

Downloaded from ajronline.org by 2800:2331:7300:162:cd27:c8e:3456:2d47 on 11/22/26 from IP address 2800:2331:7300:162:cd27:c8e:3456:2d47. Copyright ARRS. For personal use only; all rights reserved