Note: This copy is for your personal non-commercial use only. To order presentation-ready copies for distribution to your colleagues or clients, contact us at *www.rsna.org/rsnarights.*

Proximal Femoral Fractures: What the Orthopedic Surgeon Wants to Know[1]

Scott E. Sheehan, MD
Jeffrey Y. Shyu, MD
Michael J. Weaver, MD
Aaron D. Sodickson, MD, PhD
Bharti Khurana, MD

Abbreviations: AVN = avascular necrosis, STIR = short inversion time inversion-recovery, THA = total hip arthroplasty

RadioGraphics 2015; 35:0000–0000

Published online 10.1148/rg.2015140301

Content Codes: CT ER MK

[1]From the Department of Radiology, Division of Musculoskeletal Imaging and Intervention, University of Wisconsin, 600 Highland Ave, Madison, WI 53792 (S.E.S.); and Department of Radiology, Division of Emergency Radiology (J.Y.S., A.D.S., B.K.), and Department of Orthopedic Surgery (M.J.W.), Brigham and Women's Hospital, Harvard Medical School, Boston, Mass. Presented as an education exhibit at the 2013 RSNA Annual Meeting. Received September 9, 2014; revision requested November 19 and received December 15; accepted December 16. For this journal-based SA-CME activity, the authors, editor, and reviewers have disclosed no relevant relationships. **Address correspondence to** B.K. (e-mail: *bkhurana@partners.org*).

SA-CME LEARNING OBJECTIVES

After completing this journal-based SA-CME activity, participants will be able to:

- Discuss the anatomic considerations, morphologic features, and injury mechanisms of adult proximal femoral fractures.
- Describe the appropriate imaging workup for different types of proximal femoral fractures.
- List the potential complications and appropriate management strategies for these fractures.

See www.rsna.org/education/search/RG.

Each year, more than 250,000 hip fractures occur in the United States, resulting in considerable patient mortality and morbidity. The various types of adult proximal femoral fractures require different treatment strategies that depend on a variety of considerations, including the location, morphologic features, injury mechanism, and stability of the fracture, as well as the patient's age and baseline functional status. The authors discuss femoral head, femoral neck, intertrochanteric, and subtrochanteric fractures in terms of injury mechanisms, specific anatomic and biomechanical features, and important diagnostic and management considerations, including the diagnostic utility of imaging modalities. The authors review clinically important classification systems, such as the Pipkin, Garden, Pauwels, and Evans-Jensen classification systems, with emphasis on differentiating subchondral insufficiency fractures from avascular necrosis of the femoral head and typical subtrochanteric fractures from atypical (often bisphosphonate-related) subtrochanteric fractures. In addition, the authors describe the potential complications and management strategies for each fracture type on the basis of the patient's age and physical condition. A clear understanding of these considerations allows the radiologist to better provide appropriate and relevant diagnostic information and management guidance to the orthopedic surgeon. *Online supplemental material is available for this article.*

©RSNA, 2015 • *radiographics.rsna.org*

Introduction

More than 250,000 hip fractures occur in the United States annually. Most of these fractures occur in the elderly, with associated 1-year mortality rates ranging from 14% to 36% (1). The treatment of hip fractures often requires a multidisciplinary approach that includes addressing underlying medical conditions and providing appropriate surgical fixation, early mobilization, and rehabilitation to ensure a return to baseline functional mobility and independence (1). Delays in appropriate surgical treatment are associated with increased complication and mortality rates (1,2). Suboptimal treatment of hip fractures may result in debilitating complications such as avascular necrosis (AVN), fracture nonunion or malunion, or fixation hardware failure. Therefore, early detection and classification of hip fractures are essential for guiding early appropriate treatment.

In this article, we review the normal anatomy and biomechanics of the hip and discuss adult proximal femoral fractures in terms of morphologic characteristics, imaging features, prognosis, and management strategies.

TEACHING POINTS

- Osteoporosis manifests as a loss of trabecular bone rather than cortical bone and is thought to be critical in fracture predisposition, possibly by shifting the transmission of loading forces through the medial cortex at the base of the femoral neck.
- The lateral margin of the femoral head-neck junction is crucial because this is the most common penetration point of the lateral epiphyseal vessels, and fractures involving this area create a high risk of critical vascular injury, with generally decreasing risk as fractures occur more distally along the femoral neck.
- Subchondral insufficiency fractures are histologically distinct from osteonecrosis, since the former consist mainly of fracture callus and granulation tissue with marrow edema and enhancement both proximal and distal to the fracture line, in contrast to the devascularized, nonenhancing proximal-superficial bone seen in osteonecrosis. Subchondral insufficiency fractures also tend to be irregular, convex relative to the articular surface, and discontinuous, as opposed to the relatively smooth, continuous, and concave hypointense line seen in osteonecrosis.
- Valgus-impacted fractures are frequently missed on initial radiographs owing to the subtlety of cortical distortion at the femoral head-neck junction and relatively mild fracture angulation, and they are often apparent only on the basis of the presence of a characteristic sclerotic lateral cortical impaction triangle.
- Isolated fractures of the lesser trochanter in adults should be considered pathognomonic for tumor infiltration, due to the relative rarity of traumatic avulsions in this population compared with children.

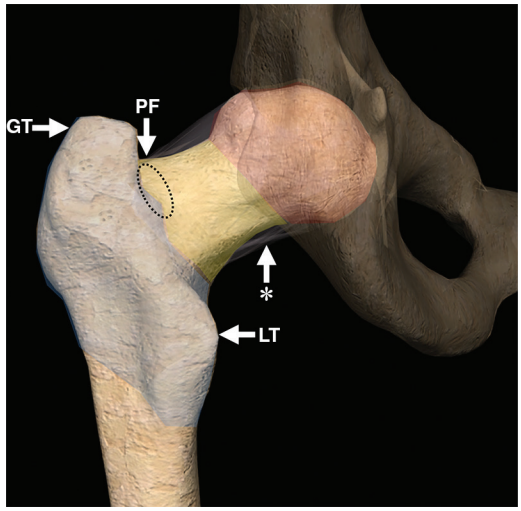

Figure 1. Computer-generated image of the posterior aspect of the proximal femur demonstrates normal anatomic landmarks and injury zones. The femoral head (red) and neck (yellow) are intracapsular, and the intertrochanteric (blue) and subtrochanteric (orange) regions are extracapsular. *GT* = greater trochanter, *LT* = lesser trochanter, *PF* = piriformis fossa, * = joint capsule.

Normal Anatomy and Biomechanics

The hip is a ball-and-socket joint composed of the femoral head and acetabulum. It is inherently stable owing to the depth of the acetabulum and surrounding labrum, allowing femoral rotation in the coronal, sagittal, and transverse planes while limiting femoral head translation (3). Forces applied to the hip are counterbalanced primarily by the combined contributions of the static bone structures and the dynamic abducting action of the gluteal muscles that attach on the greater trochanter (Fig 1) (Movie 1) (3).

Osseous support of the proximal femur is provided by the combined contributions of cortical and cancellous trabecular bone. Cortical bone and trabecular bone are both anisotropic, meaning that their strength depends on the direction of loading: They are strongest when exposed to longitudinal compression forces and weakest when exposed to tension and shear forces. Thickened trabeculae can be seen along the lines of greatest stress induced during normal weight bearing and ambulation and are thought to be the result of stress-induced bone remodeling (4,5). The inferomedial femoral neck cortex thickens notably at a point called the medial compression buttress (6). Adjacent to the medial buttress, a dense, vertically oriented plate of cortical bone called the calcar femorale extends from the posteromedial femoral cortex just below the lesser trochanter inferiorly and projects toward the margin of the greater trochanter superolaterally. The calcar femorale serves to reinforce the femoral neck and has been described as a buttress that can be used to enhance implant stability in fracture treatment (7). The calcar femorale is situated close to the convergence point of multiple lines of vertically oriented trabeculae that radiate superiorly to the primary weight-bearing portion of the femoral head. These vertically oriented trabeculae are commonly referred to as the primary compressive group, which transmits the majority of compressive forces during normal gait (5), although tensile and secondary compressive groups as well as a greater trochanteric group are also commonly described (Fig 2). Osteoporosis manifests as a loss of trabecular bone rather than cortical bone and is thought to be critical in fracture predisposition, possibly by shifting the transmission of loading forces through the medial cortex at the base of the femoral neck (5). One particular region of trabecular bone located within the inferomedial femoral neck between the converging primary and secondary compressive groups is known as the Ward triangle; this region is a site of relative weakness that is subject to disproportionate bone resorption in osteoporosis (8). Compressive forces are thought to play a key role in the formation and maintenance of compressive trabeculae, and their intersecting 60° orientation provides protection from the shear coupling produced by

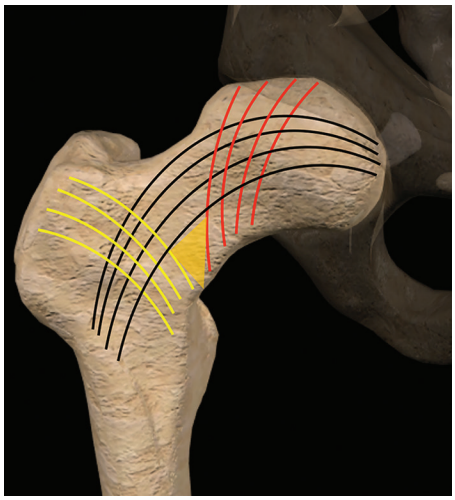

Figure 2. Computer-generated image demonstrates the orientation of the load-bearing trabeculae of the proximal femur, including the vertically oriented primary compressive trabeculae (red lines), the more horizontally oriented primary tensile trabeculae (black lines), and obliquely oriented secondary compressive trabeculae (yellow lines). The intervening trabecular bone between the medially converging compressive trabeculae is known as the Ward triangle (yellow triangle), a site of relative weakness.

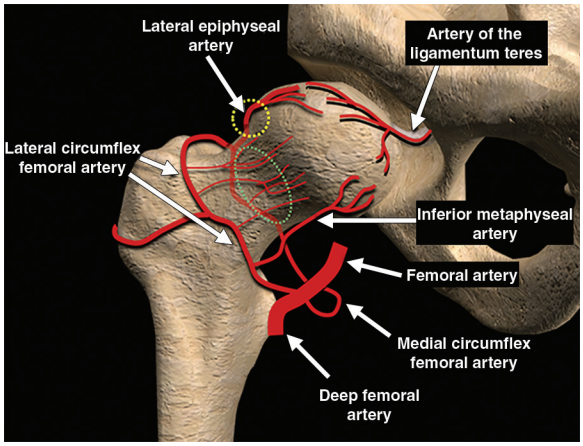

Figure 3. Computer-generated image demonstrates the vascular anatomy of the proximal femur. Blood flow to the proximal femur is supplied primarily by the branches of the medial and lateral circumflex femoral arteries. Supplemental flow to the femoral head is supplied by the artery of the ligamentum teres, a branch of the obturator artery. Green oval = transition point between the extracapsular and intracapsular portions of the ascending cervical retinacular arteries; yellow circle = lateral aspect of the femoral head-neck junction, a vulnerable zone where injury poses a substantial risk of clinically significant vascular compromise.

nonlongitudinal trabecular loading (9). Although the role of tensile forces in forming these trabeculae is controversial (4), for historical consistency, these trabeculae will be referred to as tensile or compressive trabeculae. Familiarity with the normal primary and secondary compressive and tensile trabecular lines may aid in recognizing occult or minimally displaced fractures.

The blood supply of the femoral head and neck has three distinct components: *(a)* an extracapsular arterial ring that arises from the lateral circumflex femoral artery anteriorly and the medial circumflex femoral artery posteriorly; *(b)* ascending intracapsular cervical branches of the extracapsular ring, known as retinacular arteries; and *(c)* the artery of the ligamentum teres (Fig 3) (10). The retinacular arteries course superiorly along the surface of the femoral neck and form a subsynovial ring at the articular margin (11). The medial circumflex femoral artery is generally the largest single contributor of blood supply to the femoral head, particularly its superolateral aspect including the weight-bearing portion, via the lateral epiphyseal artery complex (11,12). The lateral circumflex femoral artery supplies the anteroinferior aspect of the femoral head via the inferior metaphyseal artery (12). The artery of the ligamentum teres contributes a minor but variable amount of femoral head blood flow, variably anastomosing with the lateral epiphyseal and short medial epiphyseal branches, although this supply alone is usually insufficient to adequately perfuse the femoral head (12–14). The intracapsular course of the retinacular vessels and the subsynovial ring, and the intraosseous course of the lateral epiphyseal and inferior metaphyseal branches of the subsynovial ring predispose the hip to vascular compromise in the setting of femoral head-neck fracture (13).

Proximal Femoral Fractures

The vascular anatomy of the proximal femur plays a key role in determining the optimal treatment modality, such that fracture classification and reporting should address the likelihood of vascular compromise. Intracapsular fractures often place the tenuous femoral head blood supply at particular risk for compromise, thereby resulting in fracture nonunion and/or AVN (15). The lateral margin of the femoral head-neck junction is crucial because this is the most common penetration point of the lateral epiphyseal vessels,

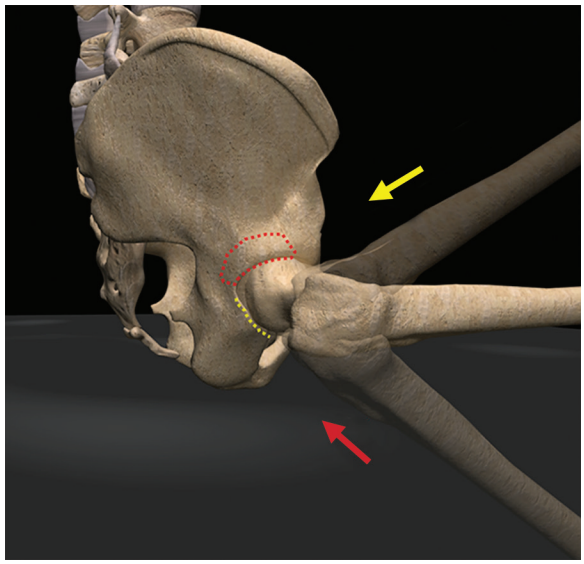

Figure 4. Computer-generated image demonstrates the force characteristics governing injury mechanisms during posterior hip dislocation. With increasing flexion, adduction, and internal rotation of the hip, axial loading of the femur (yellow arrow) is more likely to result in translation of the femoral head past the relatively narrow inferoposterior acetabular wall (yellow line) without resulting in femoral head fracture, but with a possible acetabular wall fracture. Axial loading with lesser degrees of flexion, adduction, and internal rotation (red arrow) is more likely to result in fracture dislocation of the femoral head without acetabular fracture, due to impaction of the femoral head on the strong bone of the posterior column of the pelvis (red oval). Intermediate degrees of flexion, adduction, and internal rotation can result in mixed femoral head or acetabular fractures of variable severity.

and fractures involving this area create a high risk of critical vascular injury, with generally decreasing risk as fractures occur more distally along the femoral neck (Fig 3) (13). Treatment of femoral head fractures, as well as of subcapital and transcervical femoral neck fractures, must account for potentially compromised blood flow to the femoral head and therefore must be geared toward its maintenance, restoration, or prosthetic replacement if these complications are to be prevented. In contrast, basicervical and intertrochanteric fractures demonstrate minimal risk for the disruption of vascular flow to the femoral head. Treatment of these injuries focuses on reduction of displacement and stabilization with implants to allow early mobilization and weight bearing during fracture healing. For these reasons, intracapsular and extracapsular fractures are best viewed as separate and distinct entities.

Intracapsular Fractures

Complete Femoral Head Fractures.—Fractures of the femoral head are uncommon injuries that are most often associated with posterior hip dislocations from high-energy mechanisms such as motor vehicle collisions or falls from great heights, but also from contact sports injuries, snowboarding and skiing injuries, industrial accidents, or relatively low-energy falls without dislocation (16,17). Posterior dislocation most often results from impact on the flexed knee with the hip in mild flexion and in the neutral or slightly adducted and internally rotated position, as in a "dashboard" injury mechanism (Fig 4) (18). With increasing flexion and adduction, a pure posterior dislocation is likely, with or without an acetabular fracture (Movie 2). Anterior dislocations are much less common, accounting for fewer than 10% of hip dislocations, and are usually seen with hip extension and hyperabduction (18).

Femoral head fractures are seen in 7%–15% of hip dislocations (19) and are thought to occur due to either *(a)* mechanical shearing of the femoral head on the wall of the acetabulum or *(b)* avulsion of the ligamentum teres (20). Multiple classification systems for proximal femoral fracture-dislocations have been described in the literature, but the morphologic classification system proposed by Pipkin (17) remains the most widely used (16). The Pipkin system classifies femoral head fracture-dislocations into four types, depending on the morphologic features of the femoral head fracture and the presence or absence of an associated femoral neck or acetabular fracture (Fig 5). The Pipkin system is favored due to its simplicity of use, its ability to help estimate subsequent risk of long-term complications, and its utility in directing early surgical management (16,21,22).

Femoral head fractures caudal to the fovea centralis are Pipkin 1 lesions and do not involve the weight-bearing portion of the femoral head. Fractures that extend cranial to the fovea centralis are Pipkin 2 lesions; because these fractures involve the weight-bearing portion of the femoral head, the risk of posttraumatic arthritis or AVN is increased. Pipkin 1 lesions can be treated conservatively with closed reduction if adequate postreduction congruence is achieved with less than 1-mm articular step-off (22), although primary excision of small fragments has also yielded favorable results (23). Because Pipkin 2 fracture fragments extend above the fovea centralis, they may alter the weight-bearing force distribution on the femoral head, potentially leading to accelerated cartilage disease. Pipkin 2 fracture fragments also maintain their attachment to the ligamentum teres, which

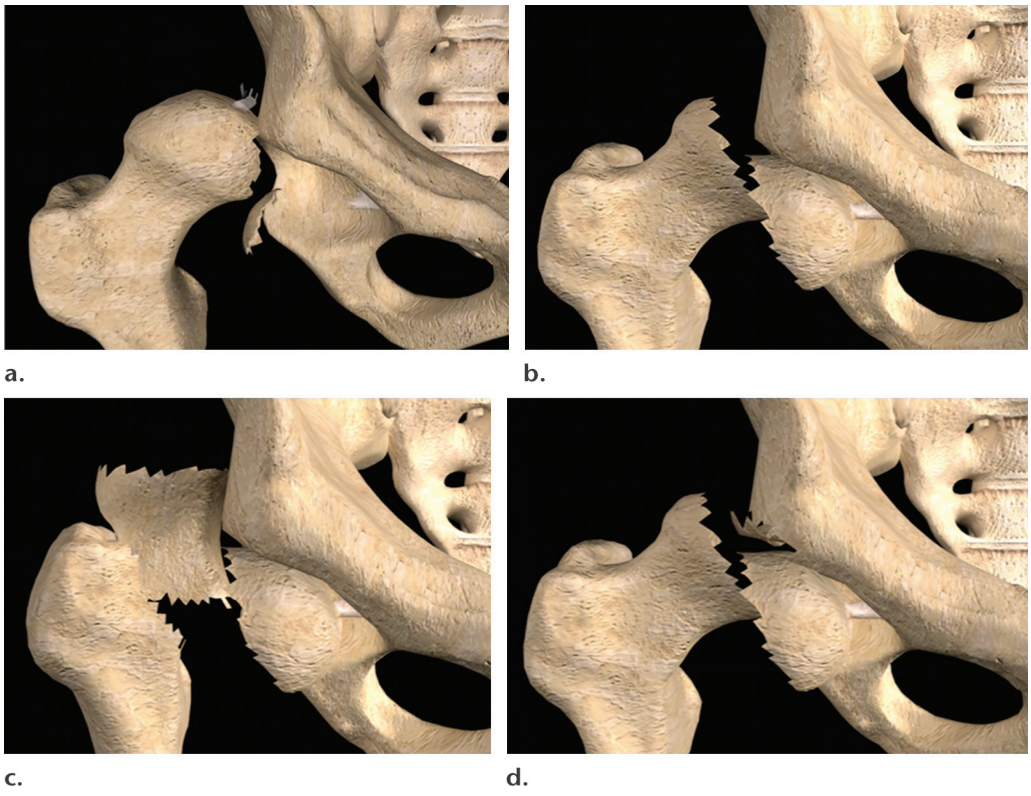

Figure 5. Computer-generated images demonstrate the Pipkin classification system for femoral head fractures. **(a)** Type 1 fractures are confined to the femoral head caudal to the fovea centralis. **(b)** Type 2 fractures extend cranial to the fovea centralis, and the ligamentum teres often remains attached to the fracture fragment. **(c)** Type 3 lesions combine a type 1 or 2 femoral head fracture with a femoral neck fracture. **(d)** Type 4 lesions combine a type 1 or 2 femoral head fracture with an acetabular fracture.

is thought to predispose the fragment to flipping, thereby complicating closed reduction due to fracture fragment interposition (17). Large, incongruous postreduction Pipkin 1 fracture fragments, as well as most Pipkin 2 fracture fragments, are best treated with anatomic reduction and internal fixation of the fragment to restore the femoral head contour (Fig 6) (22). Pipkin 3 and 4 lesions represent the combination of a type 1 or 2 femoral head fracture with either a femoral neck fracture (type 3) or acetabular fracture (type 4) (Fig 5). The presence of these other injuries substantially complicates management and portends a considerably worse prognosis.

With few exceptions, initial treatment of posterior hip dislocation consists of urgent reduction, irrespective of the presence or type of femoral head fracture, since reduction within the first few hours of injury will decrease the risk of complications such as AVN (24). Early closed reduction is favored in the vast majority of cases, including simple dislocations and fracture-dislocations involving the femoral head and acetabulum, but it is contraindicated in the setting of coexisting femoral neck fractures, as seen in Pipkin 3 lesions. When a dislocation of the hip joint coexists with a femoral neck fracture, the process of reduction may cause additional femoral neck fracture displacement, which inadvertently increases the risk of AVN (22). Urgent open reduction is indicated for Pipkin 3 injuries, as well as for cases of dislocation with failed closed reduction. In cases of native hip dislocation, it is important to scrutinize radiographs for signs of a minimally or nondisplaced femoral neck fracture, since the presence of this finding may warrant an open procedure rather than an attempt at closed reduction. Similarly, the best treatment of Pipkin 4 lesions is generally dictated by the severity and morphologic features of the coexisting acetabular fracture and most commonly involves early closed reduction and traction, followed by definitive surgical fixation of the fractures (22).

Thus, prereduction imaging should emphasize detection of occult femoral neck fractures as well as large interposed bone fragments that may impede closed reduction, although definitive reduction should not be substantially delayed in efforts to obtain cross-sectional images. Initial evaluation with anteroposterior radiography is usually acceptable, but the use of oblique or Judet views or urgent CT may be warranted to better evaluate suspected femoral head, neck, and acetabular fractures and intraarticular bone fragments impeding reduction (19). CT and/or repeat radiography with



a. b. c.

Figure 6. Postreduction anteroposterior radiograph **(a)** and coronal computed tomographic (CT) image **(b)** obtained in a 28-year-old man who had sustained a Pipkin type 2 fracture following posterior hip dislocation show a large, displaced intraarticular fracture fragment (arrow) that has maintained its attachment to the ligamentum teres and subsequently flipped, resulting in inadequate closed reduction. A radiographically occult secondary intraarticular fracture fragment is evident on the CT image. **(c)** Anteroposterior radiograph obtained following definitive open reduction and fixation demonstrates screw fixation of the flipped fragment (arrow) as well as screw fixation of a trochanteric osteotomy fragment that was induced during open reduction.

Judet views is performed following closed reduction for further evaluation of coexisting acetabular lesions, postreduction alignment, and the presence of intraarticular bodies for potential surgical planning. Radiographs of the thigh and knee should also be obtained, given the high association with concomitant fractures of the femoral shaft and patella (19,25). Magnetic resonance (MR) imaging is rarely indicated in the acute setting; it may be performed in the rare case of failed closed reduction with concern for soft-tissue interposition, but it should not delay definitive open reduction. Special care should be taken to evaluate postreduction images for signs of femoral head subluxation or an interposed soft-tissue or osseous fragment, since affected patients require surgical intervention and will benefit from skeletal traction prior to definitive fixation (26).

Femoral Head Impaction Fractures.—Osteochondral impaction fractures of the femoral head, and occasionally of the acetabulum, are also commonly seen with posterior hip dislocation but correlate more strongly with anterior dislocation (27). In the setting of posterior dislocation, these injuries are thought to occur with higher degrees of flexion and adduction than the more severe Pipkin 3 and 4 femoral head fractures described earlier (27). These injury locations correlate with the direction of dislocation, with posterior and anterior dislocation associated with anterosuperior and posterolateral femoral head impaction injuries, respectively, analogous to the compressive Hill-Sachs and reverse Hill-Sachs lesions of the proximal humerus seen with anterior and posterior glenohumeral dislocation. These injuries can be relatively occult on radiographs, which often demonstrate only subtle flattening or a focal compression defect of the femoral head corresponding to the site of impact on the corresponding acetabular rim. CT or MR imaging may be helpful in detecting these subtle lesions, and the presence and location of an osteochondral impaction fracture at imaging may imply the direction of an earlier dislocation that has been reduced prior to imaging, thereby calling the radiologist's attention to the site of a potential associated acetabular fracture (27). The presence of femoral head impaction following hip dislocation or acetabular fracture portends a worse prognosis.

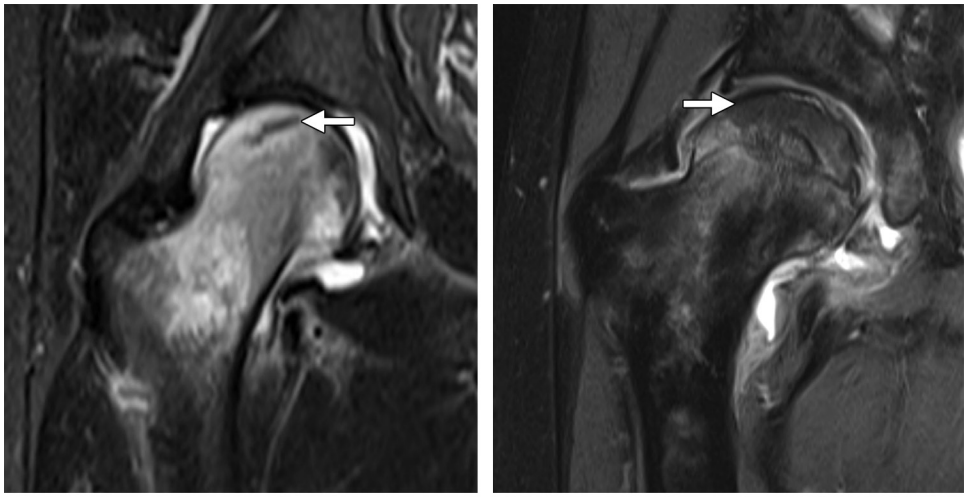

a. b.

Figure 7. **(a)** Coronal short inversion time inversion-recovery (STIR) MR image of the right hip in a 56-year-old man who complained of acute hip pain demonstrates a large area of hyperintense edema extending cranial and caudal to a hypointense subchondral fracture line (arrow), which is concave relative to the articular surface. **(b)** AVN in a 62-year-old man who was receiving chronic corticosteroid therapy. On a coronal intermediate-weighted fat-saturated MR image of the right hip, no hyperintense edema is seen cranial to the hypointense lesion rim (arrow), a finding that indicates chronic devascularized bone.

Treatment can be challenging in younger patients and is controversial. In elderly patients, impaction of the femoral head often suggests treatment consisting of reconstruction with total hip arthroplasty (THA) to replace the damaged bone.

Unlike patients with high-energy Pipkin-type fractures and traumatic osteochondral fractures, elderly patients with osteoporosis or with baseline medical diseases such as renal insufficiency may develop focal subchondral insufficiency fractures. These lesions may develop from relatively mild inciting trauma, are typically unilateral, and can be the cause of radiographically occult hip pain (28). The MR imaging appearance may be similar to that of femoral head osteonecrosis, with a T1 hypointense subchondral line superimposed on a larger area of hyperintense bone edema (Fig 7) (28). However, subchondral insufficiency fractures are histologically distinct from osteonecrosis, since the former consist mainly of fracture callus and granulation tissue with marrow edema and enhancement both proximal and distal to the fracture line, in contrast to the devascularized, nonenhancing proximal-superficial bone seen in osteonecrosis (28). Subchondral insufficiency fractures also tend to be irregular, convex relative to the articular surface, and discontinuous, as opposed to the relatively smooth, continuous, and concave hypointense line seen in osteonecrosis (29).

Osteochondral and subchondral injuries can also be seen in young, relatively healthy patients such as athletes, who are subject to repetitive microtrauma from transient subluxation or repetitive axial loading from vigorous running, aggressive jumping, or cutting maneuvers (28). At imaging, these injuries can also demonstrate focal T1 hypointense and T2 hyperintense signal with or without a hypointense line, characteristically involving the anterosuperior portion of the femoral head and thereby corresponding in location to the site of the primary compressive trabeculae. The similar imaging characteristics of these lesions necessitate interpretation in light of the clinical context, since subchondral insufficiency fractures and traumatic osteochondral lesions may be successfully treated conservatively or with femoral head–conserving surgical procedures, whereas osteonecrosis may ultimately require hip arthroplasty (28).

Femoral Neck Fractures.—The prevalence, most common injury mechanisms, classification, and treatment of femoral neck fractures depend on the patient's age and baseline functional status (1,30). Adults are generally considered to be elderly if they are older than 70–75 years, and as young or young elderly if they are younger than 65–70 years, qualified by estimated physiologic age or functional status relative to their peers (30). Femoral neck fractures are often described as subcapital, transcervical, or basicervical in location, and as either displaced or nondisplaced. These distinctions are important because the blood supply to the femoral head is at risk following fractures within the hip joint. Basicervical fractures are rarely associated with AVN and are treated differently than other intracapsular fractures. Young adults tend to have fewer femoral neck fractures than elderly individuals, who have poorer bone

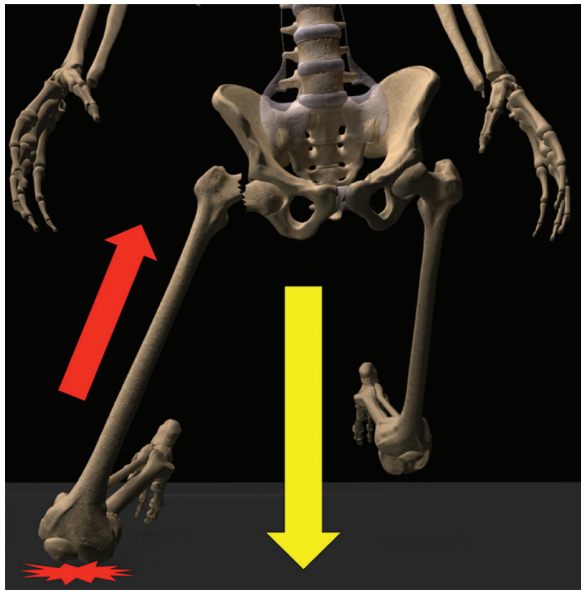

Figure 8. High-energy mechanism of femoral neck fracture. Computer-generated image demonstrates how a fall from a great height onto a flexed and abducted knee causes transmission of an axial loading force (yellow arrow) through the femur (red arrow), resulting in a distraction and shearing fracture of the femoral neck. The strong posterior acetabular column stabilizes the femoral head within the acetabulum. Red starburst = area of impact.

density; instead, young adults tend to have more vertically oriented distal neck or basicervical fractures from high-energy mechanisms in which an axial load is applied to an abducted knee, such as in an automobile accident or a fall from a great height (Fig 8) (31). Conversely, elderly individuals more commonly have transverse subcapital femoral neck fractures (or, alternately, trochanteric fractures) from low-energy mechanisms, such as a lateral fall onto the greater trochanter from a standing height (Movie 3) (7,32).

Detailed classification systems have been proposed for femoral neck fractures, but no one system has gained universal favor. The goal of treatment is to restore mobility and minimize the need for repeated surgical intervention. The method of treatment is determined on the basis of fracture location, degree of displacement, and patient factors including age and functional demands.

For elderly patients, the Garden classification system is most commonly used. This system describes four categories of prereduction subcapital fracture: incomplete or valgus impacted (stage 1), complete but nondisplaced (stage 2), complete and partially displaced (stage 3), and complete and fully displaced (stage 4) (Fig 9) (7). Younger adult patients are most often classified according to the Pauwels system, which emphasizes vertical angulation of the postreduction fracture line and describes three categories of severity, although the exact angulation measurements of each category are controversial (Fig 10) (33,34). Under the Pauwels system, higher-degree lesions imply increasing shear stress relative to compressive stress at the fracture line during ambulation, with worsening instability, progressive fracture displacement, and risk of varus collapse (33). Ideally, fracture classification systems should be both valid and reliable, facilitate communication, and help optimize treatment and prediction of outcomes. Of the most commonly used femoral neck fracture classification systems, including the Garden and Pauwels systems, none has demonstrated consistent utility in these respects (35). Despite their limitations, however, these systems remain in use because they emphasize important aspects of fracture morphology that can help guide age-specific optimal treatment.

The majority of femoral neck fractures, particularly displaced fractures (Fig 11), can be accurately characterized with properly positioned anteroposterior and lateral radiographs. Garden stage 1 fractures are by definition valgus impacted, with impaction of the lateral cortex and resulting valgus angulation. Valgus-impacted fractures are frequently missed on initial radiographs owing to the subtlety of cortical distortion at the femoral head-neck junction and relatively mild fracture angulation, and they are often apparent only on the basis of the presence of a characteristic sclerotic lateral cortical impaction triangle (36). Recent literature also describes a less common varus-impacted variant, which is thought to occur spontaneously or with only minimal trauma in the setting of osteoporosis. Varus-impacted fractures are associated with a higher nonunion rate than are the classic valgus-impacted fractures (15), possibly owing to an additional distraction injury to the lateral epiphyseal vessels. These injuries can also be difficult to diagnose radiographically; unlike with valgus-impacted fractures, however, the sclerotic line secondary to impaction is seen at the medial femoral head-neck junction. There is often medial rotation of the femoral head, resulting in a "mushroom cap" deformity that can be misconstrued as an osteophytic spur

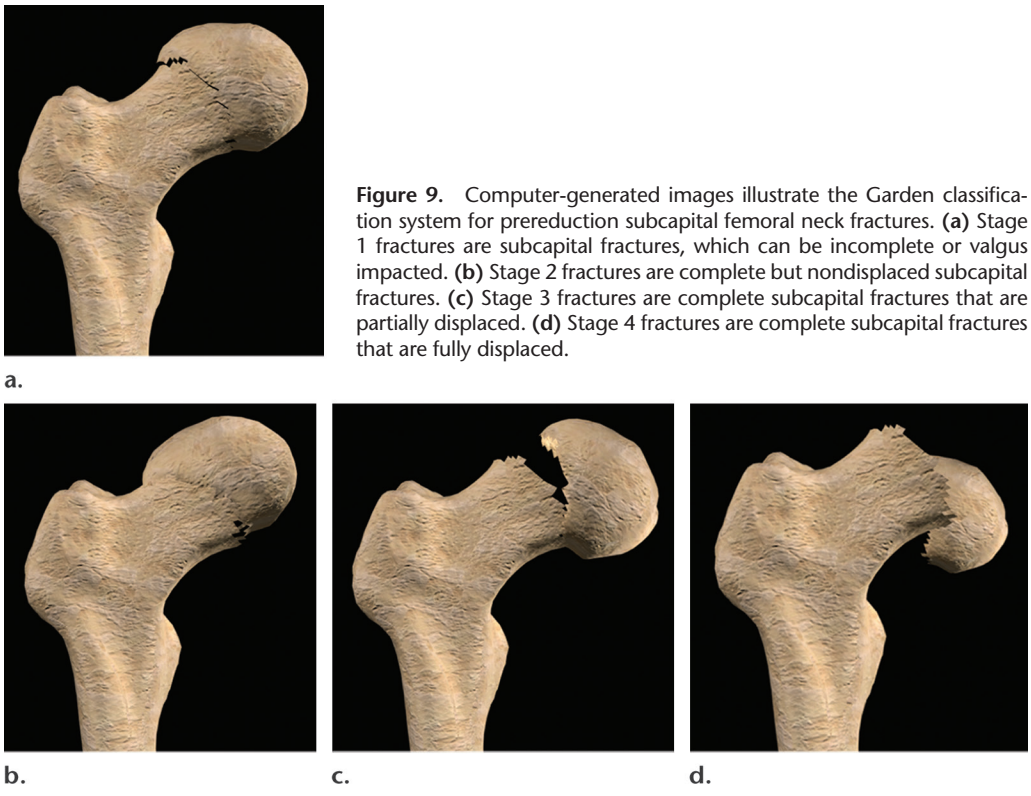

Figure 9. Computer-generated images illustrate the Garden classification system for prereduction subcapital femoral neck fractures. **(a)** Stage 1 fractures are subcapital fractures, which can be incomplete or valgus impacted. **(b)** Stage 2 fractures are complete but nondisplaced subcapital fractures. **(c)** Stage 3 fractures are complete subcapital fractures that are partially displaced. **(d)** Stage 4 fractures are complete subcapital fractures that are fully displaced.

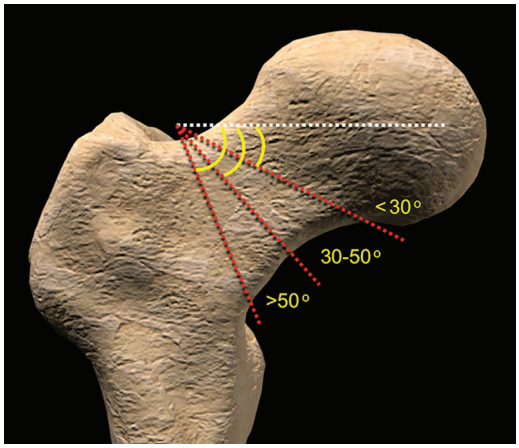

Figure 10. Computer-generated image illustrates the Pauwels classification system for postreduction femoral neck fractures as determined by the angle of the fracture relative to the horizontal plane (dashed white line). Fractures may demonstrate an angle of up to 30° (degree 1), 30°–50° (degree 2), or greater than 50° (degree 3).

(Fig 12) (37). However, although most femoral neck fractures can be seen at radiography, some are radiographically occult (38). MR imaging can be used in ambiguous cases for definitive detection and characterization of femoral neck fractures, which manifest as T1 hypointense lines superimposed on larger areas of hyperintense edema. MR imaging has the added advantage of simultaneously enabling evaluation of a wider range of potential causes of hip pain (Fig 13) (38,39). Imaging interpretation should also emphasize injury factors that are most predictive of AVN development. The reported prevalence of posttraumatic AVN in femoral neck fractures ranges from approximately 6% to 30%, with the highest prevalence in displaced fractures with poor quality of reduction, but also demonstrates a decreased prevalence in elderly populations (14). Fractures with posteromedial comminution or fracture line extension through the lateral femoral head-neck junction are particularly prone to AVN, since these fractures put the primary blood supply to the femoral head at risk (13,14). MR imaging is the most sensitive and specific imaging modality for detecting posttraumatic AVN, although signs may not be present until 48 hours after injury, and AVN is not likely to be reliably excluded with conventional MR imaging until follow-up imaging 6 months after injury (14). Perfusion MR imaging has shown promising results in predicting AVN development within 48 hours of injury, although this technique is not yet widely used (14). Early accurate imaging characterization of femoral neck fractures is critical in guiding optimal treatment planning.

Nondisplaced or impacted femoral neck fractures are most often treated with internal fixation with generally favorable results in both young and

elderly patients, with the specific fixation approach depending on the fracture pattern and surgeon preference (40). Both valgus- and varus-impacted injuries, as well as classic Garden 2 fractures, are most commonly treated with internal fixation with three cannulated lag screws. Pauwels degree 1 and 2 fractures are also most commonly treated with the use of three cannulated lag screws or, alternately, with a sliding hip screw. Pauwels degree 3 fractures are more problematic due to their higher risk of instability, and methods such as sliding hip screw or locking plate fixation have been advocated because they provide a fixed-angle construct that can more adequately resist shear forces (Fig 14) (34). Early internal fixation is critical to preventing the development of fracture displacement, since 10%–30% of fractures will ultimately become displaced if not treated (30). Nonsurgical treatment of nondisplaced fractures is usually reserved for poor surgical candidates, including nonambulatory patients with poor baseline functional status and/or clinically significant medical comorbidities.

However, optimal treatment of displaced femoral neck fractures is much more dependent on patient age and baseline functional status. The primary goal of treatment for proximal femoral fractures is restoration of the patient's normal functional mobility. In younger patients, preservation of the native femoral head allows full return to normal activity and low risk of future complications if the fracture heals (1). Compared with results in older patients, THA in younger patients is associated with a higher likelihood of prosthetic complications that may require revision at some point during the patient's lifetime (41). For these reasons, in young patients with displaced fractures, the consensus favors attempted preservation of the native femoral head by means of internal fixation (30). Although the timing of surgery is controversial, most surgeons prefer to treat these injuries on an urgent or semiurgent basis. Achieving an anatomic reduction of the femoral neck is the most important predictor of a good outcome. The risk of AVN and nonunion in young adults is highest with appreciably displaced fractures and may be more common with Pauwels degree 3 injuries (15).

There is less consensus in the literature regarding the optimal treatment of displaced femoral neck fractures in elderly patients. The generally lower daily functional demands of these patients, coupled with a relatively advanced age at the time of initial surgery, reduce the likelihood of clinically significant chronic complications of primary hip arthroplasty and the eventual need for revision (42). In addition, given the higher likelihood of preexisting osteoarthritis and the potentially higher morbidity associated with a secondary arthroplasty following failed internal fixation, primary arthroplasty is generally considered the best option for most elderly patients. Primary THA generally results in lower failure rates compared with reduction and internal fixation in elderly patients (4% versus 36% in one recent randomized control trial) (43). However, the individual risks and benefits of primary hip arthroplasty also depend on the type of hardware used, the surgeon's experience, and the patient's general state of health and baseline mobility (42). Low-demand elderly patients with displaced femoral neck fractures are typically treated with hemiarthroplasty, whereas more active elderly patients are typically treated with THA.

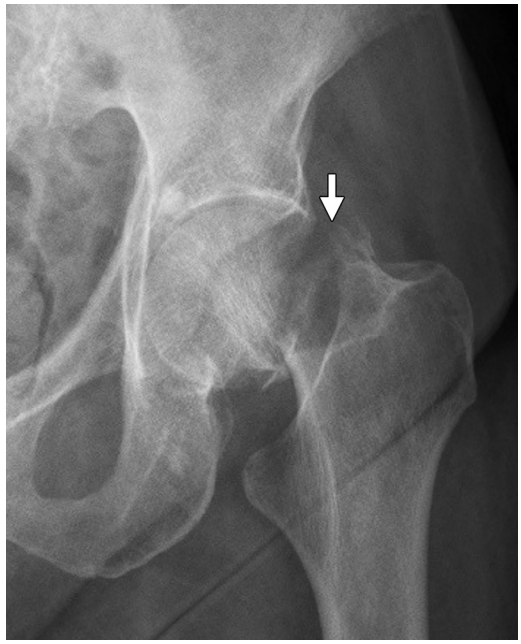

Figure 11. Prereduction anteroposterior hip radiograph in a 91-year-old woman who sustained a displaced Garden stage 4 femoral neck fracture after a fall reveals considerably distracted medial and lateral femoral cortices (arrow).

Basicervical fractures are femoral neck fractures that occur at the junction of the femoral neck base and the intertrochanteric region. Although these fractures are technically femoral neck fractures and may be intracapsular, the prevalence of AVN is thought to be low relative to subcapital and transcervical fractures. These fractures are treated like extracapsular injuries, with emphasis on reduction and fixation (44).

The term *stress fracture* describes a type of fracture that occurs due to the cumulative effects of repetitive microtrauma. Stress fractures that occur from excessive repetitive overloading of otherwise normal bone are known as fatigue fractures, whereas fractures that occur from normal loading of abnormally weakened bone are known as insufficiency fractures. Fatigue fractures are thought to occur when cumulative axial microtrauma to the

Figure 12. Valgus- and varus-impacted subcapital fractures. **(a)** Anteroposterior radiograph in an 88-year-old woman who had sustained a fall demonstrates characteristic valgus angulation of the proximal fracture fragment, a finding that is most evident due to the presence of subtle cortical overlap of the lateral femoral neck and head cortex forming a triangular opacity (arrow). **(b)** Anteroposterior radiograph of the hip in a 66-year-old woman who had sustained a fall shows a varus-impacted fracture, which can be distinguished from the more common valgus-impacted variant on the basis of the presence of a triangular opacity representing medial cortical overlap (small arrow), along with a displaced lateral cortical fracture (large arrow). **(c)** Coronal CT image of the hip in a 68-year-old woman shows a varus-impacted fracture with medial cortical overlap (triangular opacity [small arrow]), as well as a prominent, inferiorly projecting cortical rim, a finding that is often mistaken for an osteophyte (mushroom cap deformity) (large arrow).

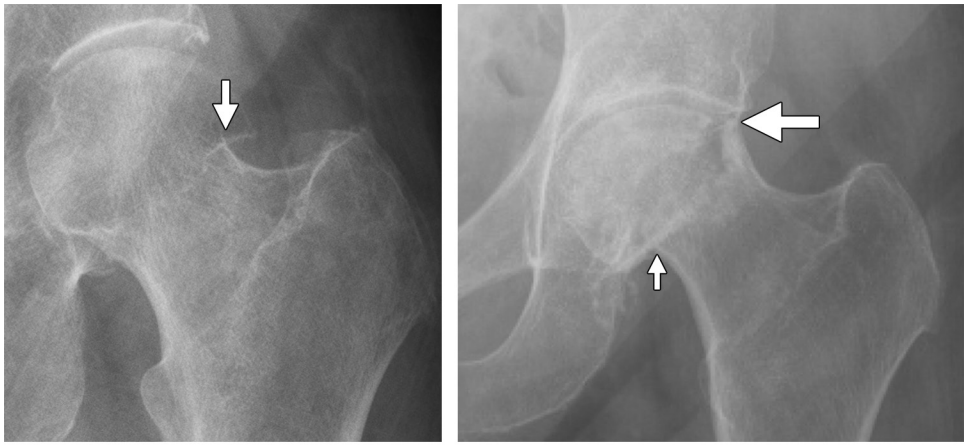

a. **b.**

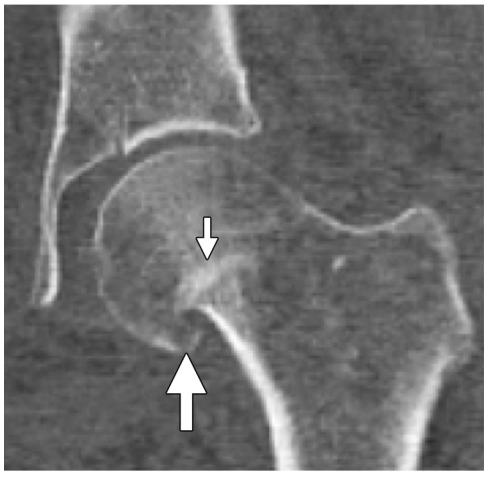

c.

femoral head is transmitted to the femoral neck, with eventual fatigue of the normally strong counterbalancing gluteus medius muscle subjecting the femoral neck to excessive bending forces (Fig 15) (3). Although fatigue fractures of the femoral neck are uncommon in the general population, they should be suspected in patients with complaints of either traumatic or atraumatic hip pain, particularly in younger, physically active patients such as elite athletes, distance runners, or military recruits (45). Insufficiency fractures more commonly occur in osteoporotic elderly patients, often without a single inciting traumatic injury (45).

Stress injuries can be further classified according to the system proposed by Fullerton and Snowdy (46) as compression-type, tension-type, and displaced fractures. Compression-type stress fractures occur at the inferomedial aspect of the femoral neck, usually near the distal cortical interface with the primary compressive trabeculae, whereas tension-type stress fractures occur at the superolateral aspect of the femoral neck, perpendicular to the tensile trabeculae. These fractures are oriented approximately 45° to the net load-bearing axis of the proximal femur (45). Compression-type stress fractures are more common in younger patients and can more often be treated conservatively due to their tendency to self-reduce with normal load bearing, whereas tension-type fractures are more common in the elderly, are insufficiency-type fractures, and are thought more likely to displace with eventual failure, thus requiring early surgical stabilization by means of internal fixation (Fig 16) (45). Early imaging detection is critical to allowing appropriate intervention before the development of fracture line widening or frank displacement, thereby preventing sequelae such as nonunion and osteonecrosis (45). Displaced fractures require urgent treatment and are treated similarly to traumatic femoral neck fractures, as described earlier (45,47).

At radiography, early stress fractures are most often occult or demonstrate subtle cortical thickening, periosteal reaction, or endosteal sclerosis, which can result in underestimation of lesion severity (48). MR imaging is the most sensitive and accurate imaging modality for detecting and grading stress injuries and has largely supplanted bone scintigraphy

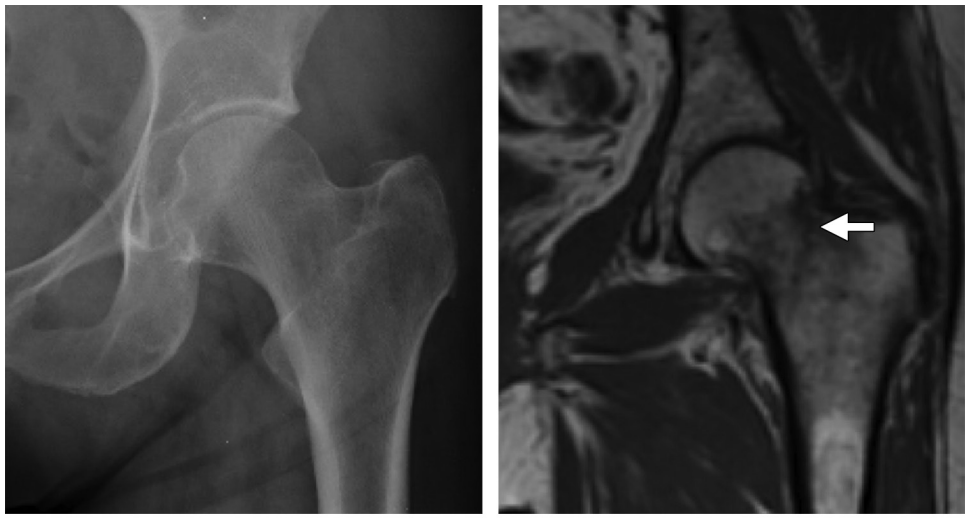

a. b.

Figure 13. Left femoral neck fracture in a 70-year-old man who had sustained a fall. **(a)** On an anteroposterior radiograph, the fracture is radiographically occult; there is no clear evidence of a cortical fracture line and no characteristic cortical overlap, as would be seen with an impacted fracture. **(b)** Coronal T1-weighted image from an abbreviated hip MR imaging study performed in the emergency department demonstrates a hypointense fracture line (arrow) that is superimposed on a larger area of hypointense edema and extends from the superolateral femoral neck cortex to near the medial compression buttress.

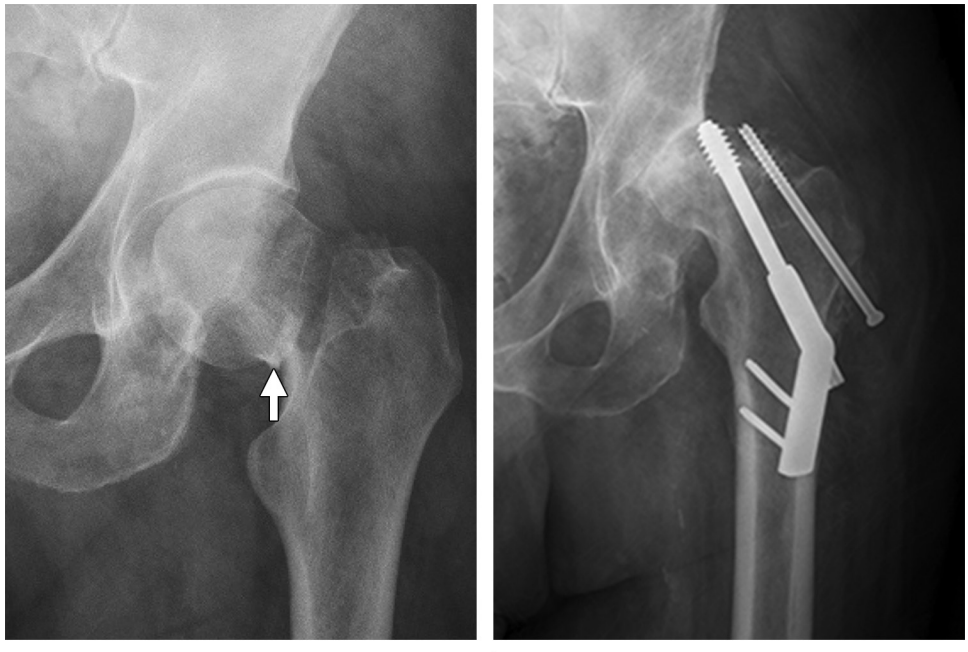

a. b.

Figure 14. Pauwels degree 3 femoral neck fracture in a 58-year-old man. **(a)** Anteroposterior radiograph of the left hip shows the fracture line (arrow) oriented approximately 70° to the horizontal plane. The patient underwent dynamic hip screw fixation. **(b)** Anteroposterior radiograph shows hardware placement. Despite undergoing screw fixation, however, the patient developed AVN and later required THA.

in the evaluation of radiographically occult injuries (48). Stress injuries show a spectrum of imaging findings that correlate with increasing injury severity, with early or low-grade stress changes manifesting as conspicuous areas of periosteal or subcortical hyperintense edema on fat-saturated T2-weighted or STIR images (49). A superimposed T1 hypointense cortical fracture line represents the most severe form of nondisplaced stress injury and should be treated as the equivalent of a nondisplaced radiographic stress fracture, with appropriate strict activity restrictions or surgical intervention as clinically appropriate (Fig 17) (49).

Extracapsular Fractures

Intertrochanteric Fractures.—Intertrochanteric fractures are most commonly seen in the elderly, with the annual prevalence and severity of intertrochanteric fractures relative to cervical fractures

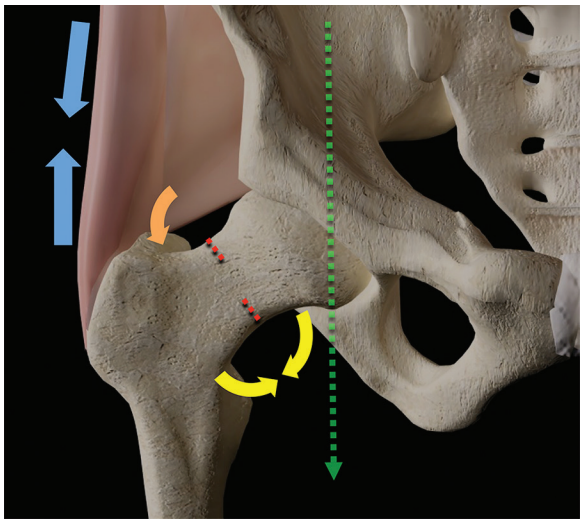

Figure 15. Computer-generated image demonstrates the location and force dynamics of a femoral neck stress fracture. The lateral position of the femoral neck relative to the skeletal axial load-bearing axis (green arrow) produces a varus-bending moment that causes compression of the medial cortex (yellow arrows) and distraction of the lateral cortex (orange arrow). Contraction of the strong gluteus medius muscle (blue arrows) counterbalances these forces, whereas gluteus medius muscle fatigue allows relatively unopposed osseous microtrauma, which may produce fatigue-type stress fractures of the medial or, less commonly, the lateral cortices (red lines).

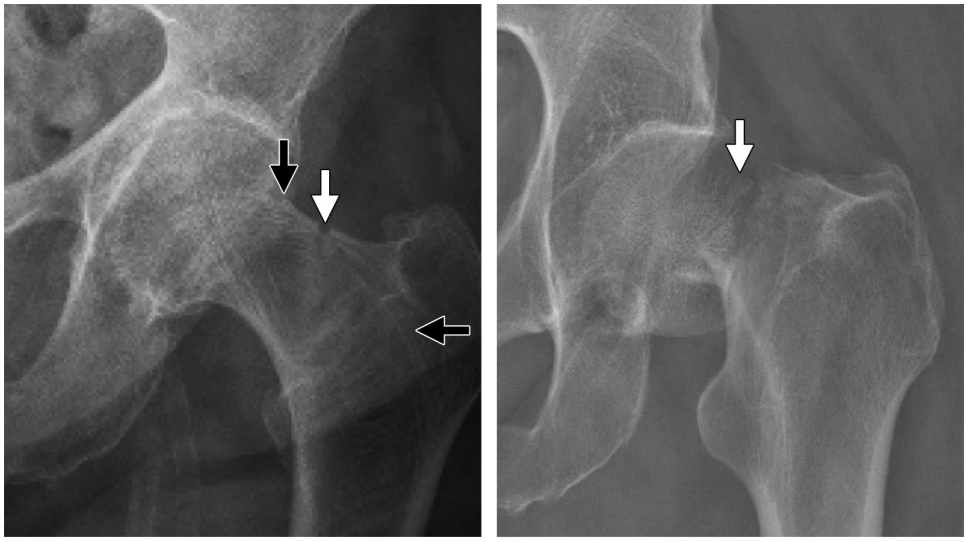

a. **b.**

Figure 16. Sequential images of the left hip in an 85-year-old woman with osteoporosis and complaints of groin pain. **(a)** Initial anteroposterior radiograph demonstrates focal disruption of the lateral femoral cortex (white arrow) with the fracture line oriented perpendicular to the primary tensile trabeculae (black arrows). The patient was diagnosed with an incomplete insufficiency-type stress fracture and was placed under strict activity restrictions. **(b)** Follow-up anteroposterior radiograph obtained after acute atraumatic exacerbation of groin pain demonstrates completion of the now-displaced femoral neck fracture (arrow).

progressively increasing in women older than 60 years (50,51). This increased prevalence is thought to correlate with worsening osteoporosis as well as decreasing average mobility and mechanical inability to successfully halt a fall (32,50,51). Intertrochanteric fractures, like the majority of hip fractures in the elderly, most commonly occur following a lateral fall with impact on the greater trochanter (32,50), with the overall intertrochanteric fracture risk, severity, and prevalence of unstable fracture morphologies correlating with the severity of trochanteric osteoporosis (51). Although impact direction has been shown to affect the overall risk of hip fracture, there is no clear correlation between impact direction and fracture location or morphology (52).

Intertrochanteric fractures are extracapsular and have a much more robust osseous blood supply, and therefore are much less likely to result in chronic complications such as AVN or nonunion. Thus, the primary concerns of inadequate treatment of trochanteric fractures are related to the risks of acute instability and possible chronic malunion with postinjury deformity (53). The majority of the orthopedic literature focuses on the treatment of complete intertrochanteric fractures, although we also discuss incomplete fractures later in this article.

Several classification systems for intertrochanteric fracture have been proposed, but none has shown sufficient reproducibility to warrant

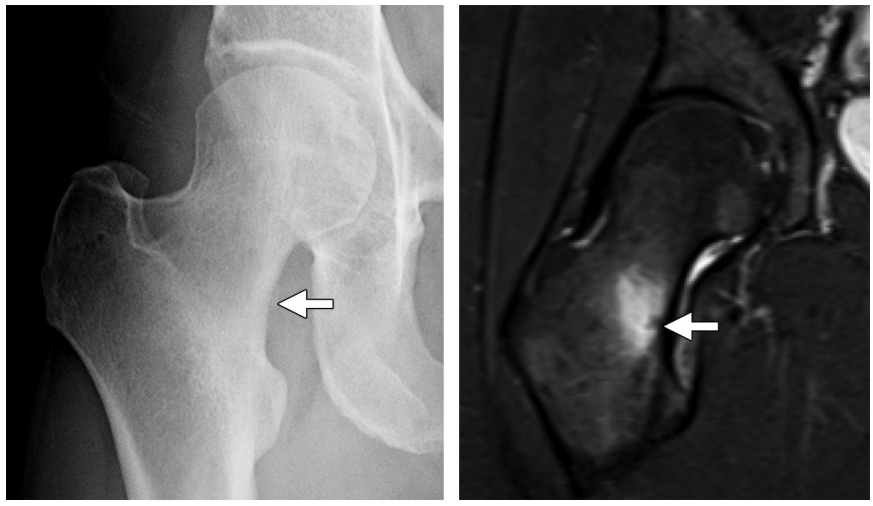

Figure 17. (a) Anteroposterior radiograph of the right hip in a 54-year-old woman with complaints of chronic hip and groin pain demonstrates subtle periosteal reaction and medial cortical thickening in the region of the Ward triangle (arrow). **(b)** Coronal image from a follow-up STIR MR imaging study reveals a hypointense stress fracture line through the medial femoral cortex superimposed on an area of hyperintense edema (arrow).

a. **b.**

widespread adoption (54). One system proposed by Evans (55) and later modified by Jensen (56) is sometimes used in the orthopedic community, owing to its relative simplicity and its emphasis on predicting the risk of postreduction fracture instability (Fig 18). According to the Evans-Jensen system, two-part oblique fractures extending from the greater to the lesser trochanter are classified as type 1 or 2, depending on the absence (type 1) or presence (type 2) of displacement. These fractures generally demonstrate adequate reduction and good postreduction stability, since the medializing force of the strong adductor muscles tends to keep the proximal and distal fracture fragments in close apposition (47,56). Type 3 and 4 fractures are comminuted fractures with three primary fracture parts, with comminution of the posterolateral (type 3) or posteromedial (type 4) cortex; these fractures often demonstrate poor postreduction alignment and are unstable. Type 5 fractures are injuries with four or more parts, with comminution of both the posteromedial and posterolateral cortices resulting in poor reduction and gross instability (Figs 18, 19). A reverse obliquity fracture is a rare subtype in which the primary fracture line extends from the medial peritrochanteric cortex inferolaterally to the subtrochanteric region (56). These fractures are particularly unstable, since the strong adductor musculature tends to worsen medial displacement of the inferior fracture fragment, subsequently increasing its proximal displacement on axial loading (Fig 20) (47). In describing intertrochanteric fractures, the radiologist should make note of the anatomic extent, including involvement of the calcar femorale, greater trochanter, lesser trochanter, and subtrochanteric region, in addition to the presence or absence of comminution, displacement, and a reverse obliquity pattern (Figs 18, 19).

The goal of treatment for intertrochanteric hip fractures is to restore mobility and allow early weight bearing. Most intertrochanteric hip fractures occur in the elderly, and there is good evidence that early surgical intervention and weight bearing improve patient outcomes and lower mortality (57,58). The standard of practice is to perform surgical fixation of nearly all intertrochanteric fractures in patients without disqualifying medical comorbidities or baseline immobility. The method of fixation is controversial, with the two primary treatment options being *(a)* lateral plate and screw fixation and *(b)* intramedullary nail fixation (59–62). There is no clear consensus regarding which implant is optimal for treating simple fracture patterns, although these injuries generally demonstrate an excellent response and low complication rate with both plate and screw fixation and intramedullary fixation techniques. The choice of implant for more complex fracture patterns is controversial (Fig 21) (59,60).

Incomplete intertrochanteric fractures most commonly involve the greater trochanter, but they do not extend to the medial femoral cortex (63). Initial imaging diagnosis and classification of intertrochanteric fractures can be problematic if the fractures are incomplete or nondisplaced; although the greater trochanteric portion is often detected, the distal extent of the fracture line is often underestimated on initial radiographs (63). Early accurate classification is critical, since the rare isolated greater trochanteric fracture can be treated conservatively, but incomplete intertrochanteric fractures are most often treated with surgical fixation, similar to other intertrochanteric fractures (63,64). MR imaging is more accurate than CT or bone scintigraphy in detecting whether greater trochanteric fractures have occult intertrochanteric or cervical extension and should be routinely

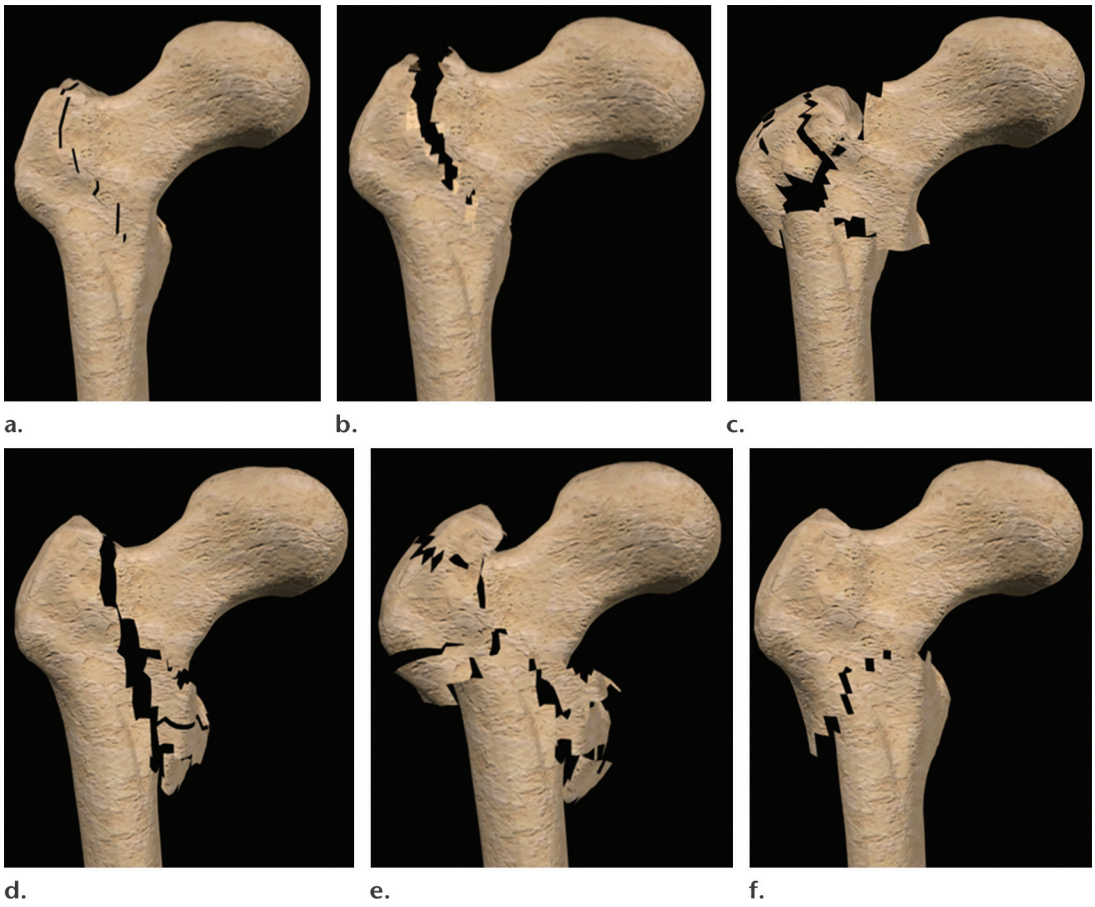

Figure 18. Computer-generated images illustrate the Evans classification system (as modified by Jensen) for intertrochanteric fractures. **(a)** Type 1 fractures are two-part fractures without displacement. **(b)** Type 2 fractures are two-part fractures with displacement. **(c)** Type 3 fractures are three-part fractures with posterolateral cortex comminution. **(d)** Type 4 fractures are three-part fractures with posteromedial cortex comminution. **(e)** Type 5 fractures consist of four or more parts with both medial and lateral cortical comminution. **(f)** A reverse obliquity fracture is a key variant, extending from the medial peritrochanteric cortex inferolaterally to the subtrochanteric cortex.

performed in high-risk or osteoporotic patients to help identify patients at risk for fracture extension or displacement (Fig 22) (65,66). Nondisplaced or partial intertrochanteric fractures are often surgically stabilized to prevent propagation and completion, subsequent displacement, or other injuries that may require a more invasive surgical approach (63,66).

Finally, isolated fractures of the lesser trochanter in adults should be considered pathognomonic for tumor infiltration, due to the relative rarity of traumatic avulsions in this population compared with children (67). These injuries can usually be detected on anteroposterior and lateral radiographs (Fig 23), although the presence of isolated fractures should prompt imaging workup for metastatic disease, including hip MR imaging and whole-body imaging for staging (67).

Subtrochanteric Fractures.—The subtrochanteric region of the proximal femur is most commonly defined as extending from the lesser trochanter to a point 5 cm distal, but it has also been described as extending as far as the femoral isthmus, the point of narrowest intramedullary diaphyseal diameter (68,69). This region is subject to particularly high biomechanical stress during normal weight bearing and ambulation (68). These relatively high mechanical stresses, coupled with the pull of the muscles attaching to the proximal fragment, make subtrochanteric fractures particularly challenging to treat, and these fractures have a higher rate of complications such as nonunion and implant failure (68). These injuries can be grouped epidemiologically into three distinct populations: *(a)* patients generally younger than age 50 years with high-energy trauma resulting in comminuted fractures; *(b)* elderly patients with likely baseline osteoporosis with lower-energy trauma such as from falls from a standing height, resulting in less comminuted spiral fractures ("typical" insufficiency fractures); and *(c)* patients with medical comorbidities or who are receiving pharmacologic treatment such as long-term (>5 years) bisphosphonate therapy, which results in impaired bone remodeling, leading to stress fracture development with subsequent

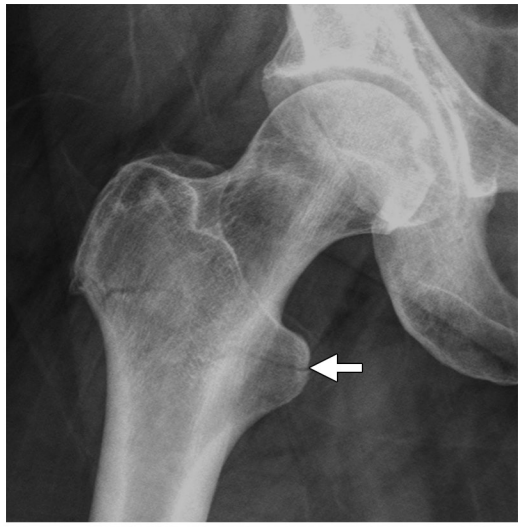

a.

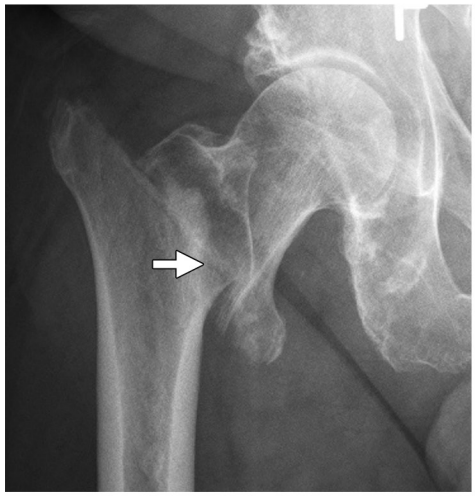

b.

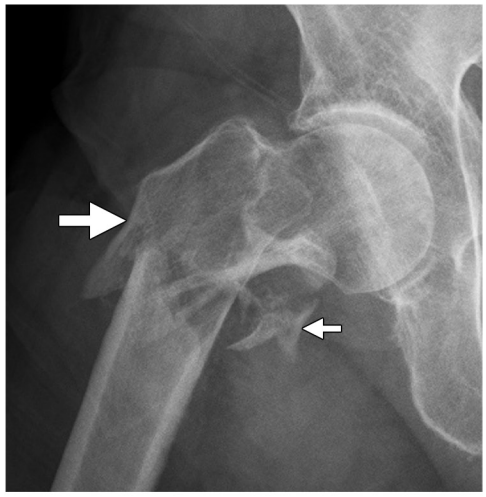

c.

Figure 19. Intertrochanteric fractures with various morphologic features in women between ages 65 and 80 years. **(a)** Anteroposterior radiograph shows a type 1 fracture, which is apparent only as a nondisplaced fracture line extending through the lateral and medial cortex (arrow). **(b)** Anteroposterior radiograph obtained in a different patient shows a type 2 fracture that is moderately displaced but still reflects a mechanically stable injury (arrow). **(c)** Anteroposterior radiograph obtained in a third patient shows a more severe type 5 fracture with comminution of both the posteromedial (small arrow) and posterolateral (large arrow) cortices, findings that indicate a highly unstable injury.

Figure 20. Computer-generated image of the hip demonstrates the reducing or distracting action of the pelvic musculature in the setting of an Evans-Jensen type 2 intertrochanteric fracture (green line) versus a reverse obliquity fracture (red line). The medial femoral insertion of the strong adductor musculature is distal to the medial cortical fracture line margins, which in the case of a type 2 fracture causes adduction (yellow arrow) with subsequent reduction and apposition of the fracture fragments in conjunction with the abducting action of the gluteus medius and minimus muscles (green arrow), resulting in relative fracture stability. In reverse obliquity fractures, the strong adductor and gluteus muscles produce net medial displacement of the distal fracture fragment.

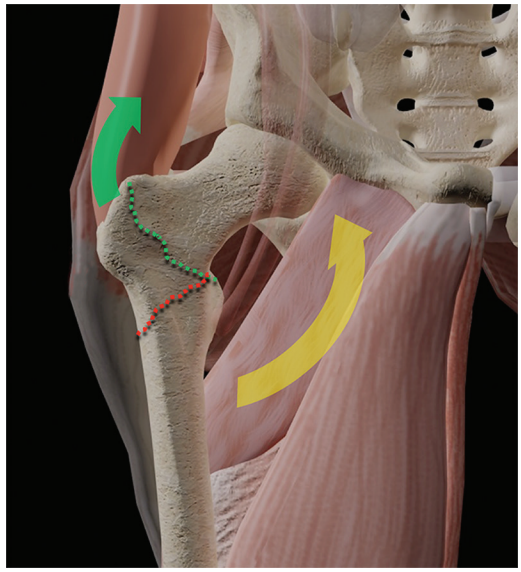

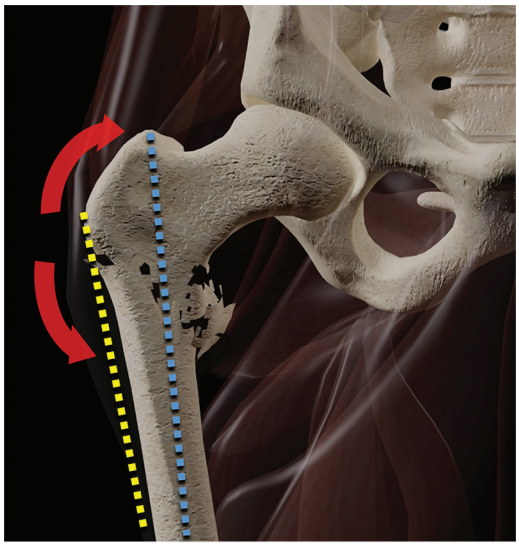

Figure 21. Computer-generated image of the left hip demonstrates an unstable intertrochanteric fracture with posteromedial comminution, causing a varus-bending moment (arrows) on normal load bearing. A lateral plate and screw fixation device has a more lateral load-bearing axis (yellow line) than does an intramedullary nail device (blue line), resulting in a greater varus-bending moment and possibly increasing the risk of hardware loosening or failure.

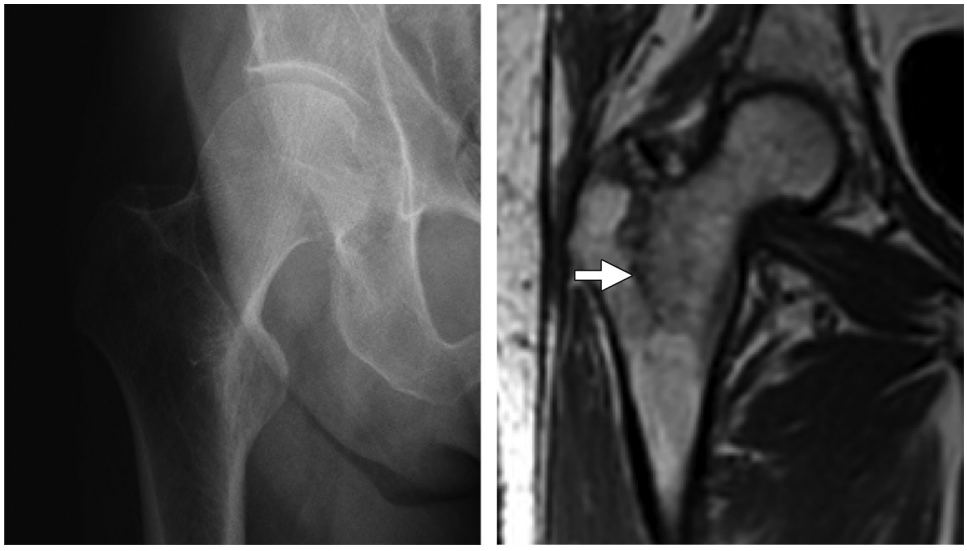

a. **b.**

Figure 22. Incomplete intertrochanteric fracture in a 54-year-old man with right hip pain who had tripped and fallen from a standing position. **(a)** Initial anteroposterior radiograph shows no evidence of fracture. MR imaging was performed in the acute setting to evaluate for occult fracture. **(b)** Coronal T1-weighted MR image of the right hip demonstrates a hypointense fracture line involving the medial cortex of the greater trochanter near the piriformis fossa and extending inferomedially toward the medial femoral cortex (arrow).

atraumatic or minimally traumatic progression ("atypical" insufficiency fractures) (68,70). These underlying causes of injury can often be distinguished by knowing the underlying injury mechanisms and characteristic radiographic features, although the specificity of these imaging findings has not been definitively established.

As with other hip fractures, the goal of treatment is to restore mobility and allow early weight bearing. The treatment of subtrochanteric fractures is made considerably more difficult by the high mechanical demands of the proximal femur and the pull of major muscle groups inserting into the proximal fragment. Typical displacement includes flexion (from the pull of the iliopsoas muscle), abduction (from the pull of the gluteus medius and minimus muscles), and external rotation (from the pull of the piriformis and short external rotator muscles). To achieve adequate stability, an intramedullary nail is most often used. Reduction can be difficult, and an open approach with direct reduction is often required.

Although there is no universally accepted classification scheme, the system described by Russell and Taylor is often used in the orthopedic community, owing to its simplicity and its emphasis on guiding surgical treatment and planning (47,68). The Russell-Taylor system divides subtrochanteric

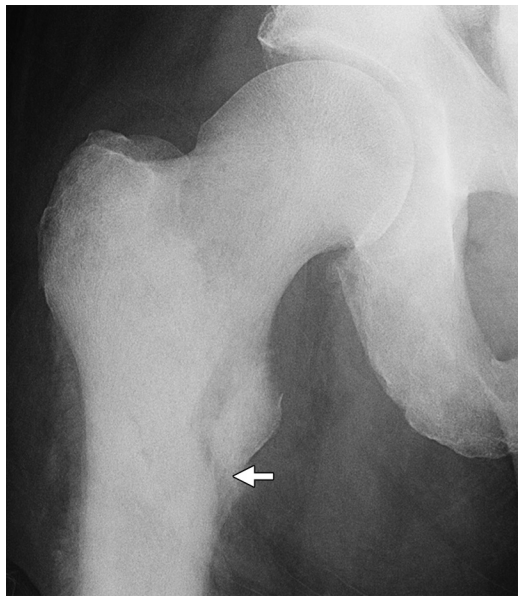

Figure 23. Isolated fracture of the lesser trochanter in a 73-year-old man with diffuse sclerotic-osseous metastatic prostate cancer who complained of acute-onset thigh pain. Anteroposterior radiograph of the right hip demonstrates an apparent isolated fracture of the lesser trochanter (arrow).

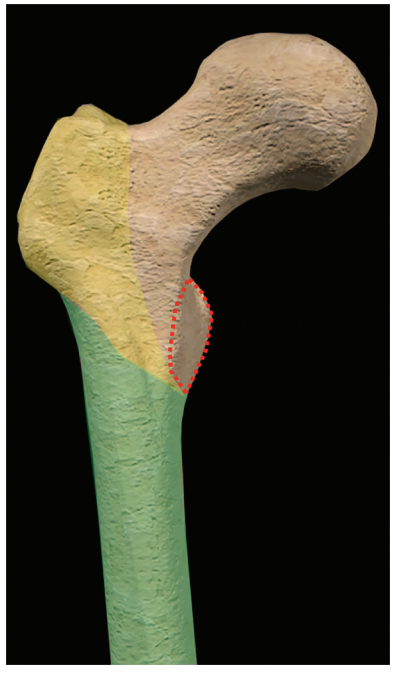

Figure 24. Computer-generated image illustrates the Russell-Taylor classification system for subtrochanteric femoral fractures. Type 1A fractures occur within a zone involving the lateral and medial subtrochanteric femoral cortex, but they spare the piriformis fossa and lesser trochanter (green). Type 1B fractures are similar to 1A fractures, with a separate lesser trochanter fracture fragment (red line). Type 2A fractures involve the piriformis fossa, the potential entry site for intramedullary rod placement, and extend to the subtrochanteric femoral cortex medially (green and yellow). Type 2B fractures are similar to type 2A fractures but, like type 1B fractures, include a separate lesser trochanter fracture fragment.

fractures into two main types based on the absence (type 1) or presence (type 2) of piriformis fossa extension, with type 2 indicating intertrochanteric extension. Furthermore, each of these two main types includes two subtypes based on the absence (subtype A) or presence (subtype B) of a lesser trochanter–posteromedial femoral cortical fracture fragment (Fig 24). The Russell-Taylor system also acknowledges the tendency toward fracture distraction and angulation due to the relatively unopposed muscle insertions at each of the fracture fragments (Fig 25). The integrity of both the piriformis fossa and the posteromedial cortex of the femur is important for determining surgical approach and implant choice (Fig 26).

The identification of an atypical subtrochanteric fracture is important. This injury is often a simple transverse or short oblique fracture. Careful examination of radiographs may reveal thickening of the lateral femoral cortex or the presence of a "beak" through which the fracture has propagated (Fig 27) (70). Although initial treatment is similar to that for other subtrochanteric fractures, prognosis and long-term management vary. A vast majority of typical subtrochanteric fractures heal, whereas the failure rate in atypical fractures is likely much higher. In one recent series, 46% of patients with atypical fractures demonstrated poor fracture healing that required repeat procedures, compared with less than 1% in traditional populations (71). When atypical femoral fractures are associated with bisphosphonate use, bisphosphonates are typically discontinued, and alternative treatments for osteoporosis such as teriparatide may be considered (72).

It is important to identify patients with nondisplaced femoral stress fractures, since they are at risk for developing an atypical femoral

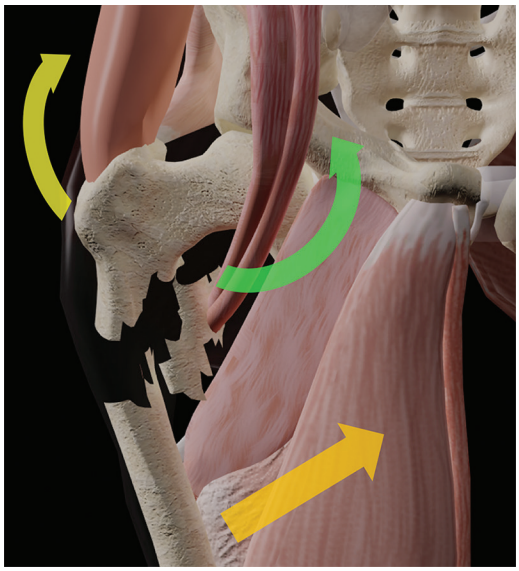

Figure 25. Computer-generated image demonstrates the distracting forces applied to subtrochanteric fracture fragments at the key muscle insertions. The greater trochanter fragment is abducted and laterally angulated by the strong gluteus medius and minimus muscles (yellow arrow); the lesser trochanter fragment is anteromedially displaced and externally rotated by the iliopsoas muscle (green arrow); and the distal femoral fragment is adducted and medially displaced by the adductor musculature (orange arrow).

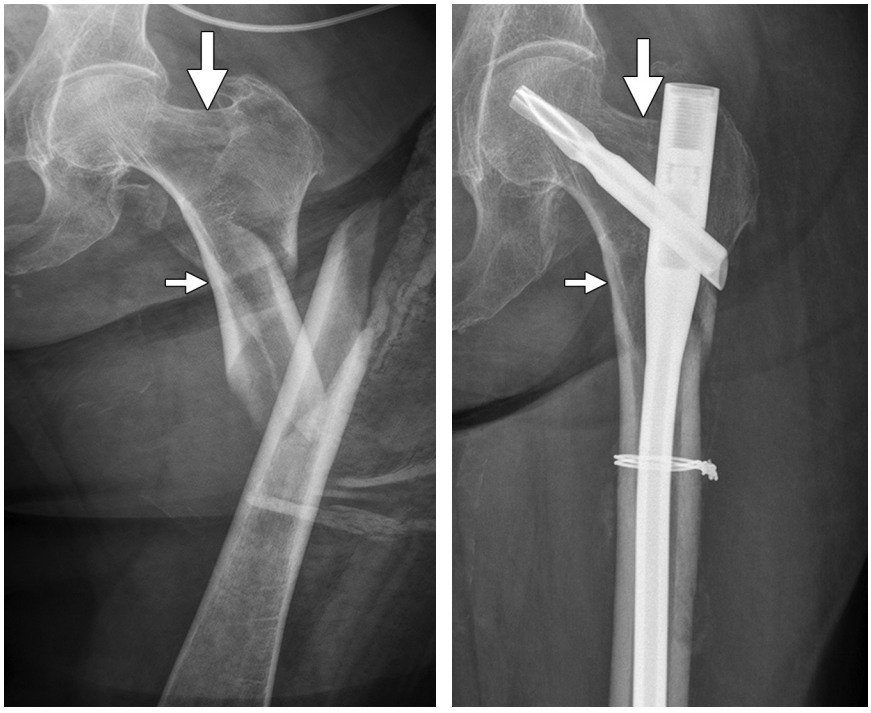

a. **b.**

Figure 26. Type 1B subtrochanteric fracture in an 84-year-old woman who complained of hip pain after sustaining a fall. **(a)** Initial anteroposterior radiograph shows a comminuted subtrochanteric fracture with spiral fracture components that completely disrupt the lateral and medial femoral cortex and compromise the posteromedial femoral cortex and lesser trochanter (small arrow) but spare the piriformis fossa (large arrow). The fracture was classified as type 1B. **(b)** Postfixation anteroposterior radiograph demonstrates an intramedullary nail that was introduced at a piriformis fossa entry site (large arrow), with a cephalomedullary fixation screw. Compromise of the posteromedial cortex and lesser trochanter is again noted (small arrow), which precludes the use of a transtrochanteric centromedullary fixation screw.

subtrochanteric fracture. Radiographs will demonstrate signs of lateral cortical thickening (beaking). Focal marrow, endosteal, or periosteal edema may be seen at MR imaging. Subtrochanteric fracture location has also been shown to correlate with the ultimate need for surgical fixation (73), although the literature is inconclusive. Close clinical and imaging surveillance during a trial of conservative therapy may be used in minimally symptomatic patients, although prophylactic fixation of incomplete fractures is most often used due to the high failure rate of conservative therapy (70).

If an atypical fracture is suspected, radiographs of the contralateral femur should be obtained and carefully inspected for an occult lesion. Although evidence is limited, some patients who present with a displaced atypical subtrochanteric femoral fracture also have a nondisplaced stress fracture in the contralateral femur (74). Prophylactic fixation is often recommended to prevent fracture propagation and displacement (70).

Conclusion

Adult proximal femoral fractures can be categorized in ways that highlight morphologic features,

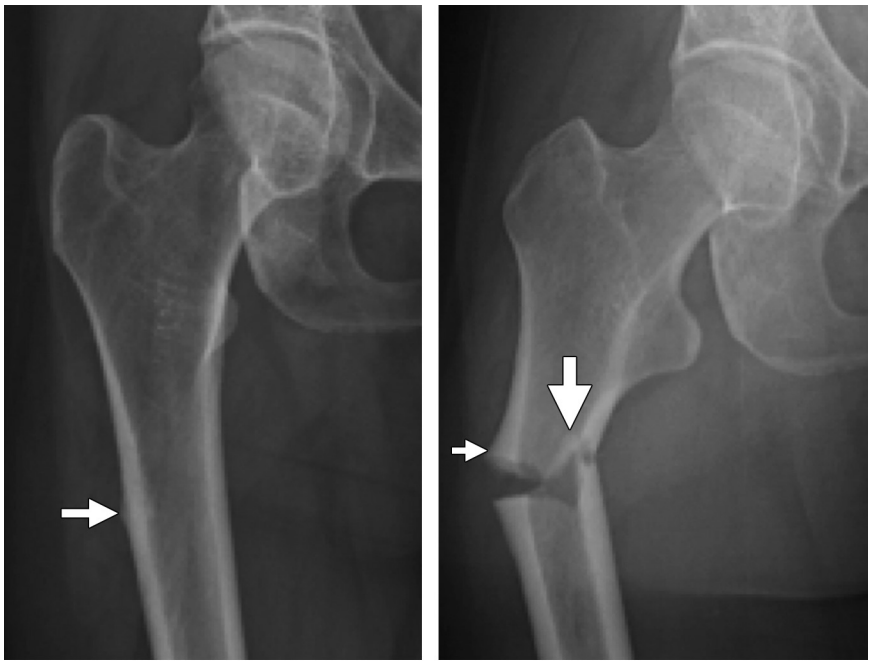

Figure 27. Atypical subtrochanteric fracture in a 65-year-old woman who was receiving bisphosphonate treatment. The patient initially presented to the emergency department with thigh pain. **(a)** Anteroposterior radiograph of the right hip demonstrates focal thickening of the subtrochanteric lateral femoral cortex with a superimposed, hypodense, incomplete cortical fracture line (arrow) that appears similar to a stress fracture. The surrounding medial and lateral subtrochanteric femoral cortex is of normal thickness. The patient was referred for outpatient orthopedic follow-up but had atraumatic completion of a noncomminuted transverse fracture. **(b)** Follow-up radiograph demonstrates a transverse fracture line with focal thickening of the lateral femoral cortex (small arrow), along with spiking of the fractured medial femoral cortex (large arrow).

a. **b.**

imaging protocol, and surgical management (Table), allowing the radiologist to best guide appropriate clinical management.

References

1. Zuckerman JD. Hip fracture. N Engl J Med 1996;334(23):1519–1525.
2. Grigoryan KV, Javedan H, Rudolph JL. Orthogeriatric care models and outcomes in hip fracture patients: a systematic review and meta-analysis. J Orthop Trauma 2014;28(3):e49–e55.
3. Nordin M, Frankel VH. Basic biomechanics of the musculoskeletal system. 3rd ed. Philadelphia, Pa: Lippincott Williams & Wilkins, 2001; 202–221.
4. Hammer A. The paradox of Wolff's theories. Ir J Med Sci 2014 Jan 29. [Epub ahead of print]
5. Lotz JC, Cheal EJ, Hayes WC. Stress distributions within the proximal femur during gait and falls: implications for osteoporotic fracture. Osteoporos Int 1995;5(4):252–261.
6. Griffin JB. The calcar femorale redefined. Clin Orthop Relat Res 1982;(164):211–214.
7. Garden R. Low-angle fixation in fractures of the femoral neck. J Bone Joint Surg Br 1961;43-B(4):647–663.
8. Qian JG, Song YW, Tang X, Zhang S. Examination of femoral-neck structure using finite element model and bone mineral density using dual-energy X-ray absorptiometry. Clin Biomech (Bristol, Avon) 2009;24(1):47–52.
9. Pidaparti RM, Turner CH. Cancellous bone architecture: advantages of nonorthogonal trabecular alignment under multidirectional joint loading. J Biomech 1997;30(9):979–983.
10. Crock HV. An atlas of the arterial supply of the head and neck of the femur in man. Clin Orthop Relat Res 1980;(152):17–27.
11. Chung SM. The arterial supply of the developing proximal end of the human femur. J Bone Joint Surg Am 1976;58(7):961–970.
12. Trueta J, Harrison MH. The normal vascular anatomy of the femoral head in adult man. J Bone Joint Surg Br 1953;35-B(3):442–461.
13. Claffey TJ. Avascular necrosis of the femoral head: an anatomical study. J Bone Joint Surg Br 1960;42-B:802–809.
14. Ehlinger M, Moser T, Adam P, et al. Early prediction of femoral head avascular necrosis following neck fracture. Orthop Traumatol Surg Res 2011;97(1):79–88.
15. Damany DS, Parker MJ, Chojnowski A. Complications after intracapsular hip fractures in young adults: a meta-analysis of 18 published studies involving 564 fractures. Injury 2005;36(1):131–141.
16. Ross JR, Gardner MJ. Femoral head fractures. Curr Rev Musculoskelet Med 2012;5(3):199–205.
17. Pipkin G. Treatment of grade IV fracture-dislocation of the hip. J Bone Joint Surg Am 1957;39-A(5):1027–1042, passim.
18. Kain MSH, Tornetta P III. Hip dislocations and fractures of the femoral head. In: Bucholz RW, Court-Brown CM, Heckman JD, Tornetta P III, eds. Rockwood and Green's fractures in adults. 7th ed. Philadelphia, Pa: Lippincott Williams & Wilkins, 2010; 1524–1560.
19. Brooks RA, Ribbans WJ. Diagnosis and imaging studies of traumatic hip dislocations in the adult. Clin Orthop Relat Res 2000;(377):15–23.
20. Davis JB. Simultaneous femoral head fracture and traumatic hip dislocation. Am J Surg 1950;80(7):893–895.
21. Brumback RJ, Kenzora JE, Levitt LE, Burgess AR, Poka A. Fractures of the femoral head. Hip 1987:181–206.
22. Asghar FA, Karunakar MA. Femoral head fractures: diagnosis, management, and complications. Orthop Clin North Am 2004;35(4):463–472.
23. Chen ZW, Lin B, Zhai WL, et al. Conservative versus surgical management of Pipkin type I fractures associated with posterior dislocation of the hip: a randomised controlled trial. Int Orthop 2011;35(7):1077–1081.
24. Sahin V, Karakaş ES, Aksu S, Atlihan D, Turk CY, Halici M. Traumatic dislocation and fracture-dislocation of the hip: a long-term follow-up study. J Trauma 2003;54(3):520–529.
25. Rupp JD, Schneider LW. Injuries to the hip joint in frontal motor-vehicle crashes: biomechanical and real-world perspectives. Orthop Clin North Am 2004;35(4):493–504, vii.
26. Schatzker J. Fractures of the femur. In: Schatzker J, Tile M, eds. The rationale of operative fracture care. 3rd ed. New York, NY: Springer, 2005; 385–408.
27. Tehranzadeh J, Vanarthos W, Pais MJ. Osteochondral impaction of the femoral head associated with hip dislocation: CT study in 35 patients. AJR Am J Roentgenol 1990;155(5):1049–1052.
28. Yamamoto T. Subchondral insufficiency fractures of the femoral head. Clin Orthop Surg 2012;4(3):173–180.
29. Ikemura S, Yamamoto T, Motomura G, Nakashima Y, Mawatari T, Iwamoto Y. MRI evaluation of collapsed

Morphologic Features, Imaging Protocol, and Surgical Management of Adult Proximal Femoral Fractures

Type of Fracture	Morphologic Features	Imaging Protocol	Surgical Management
Femoral head			
Complete	Associated with posterior hip dislocation Pipkin 1: below fovea centralis Pipkin 2: above fovea centralis (weight bearing) Pipkin 3: with femoral neck fracture Pipkin 4: with acetabular fracture	Prereduction: radiography or CT performed within 1 hour of presentation to evaluate morphologic characteristics of fracture and exclude femoral neck fracture Postreduction: radiography or CT used to evaluate for congruency or failed reduction	Pipkin 1: closed reduction, conservative treatment or ORIF Pipkin 2: closed reduction, ORIF Pipkin 3: urgent open reduction with ORIF Pipkin 4: closed reduction and traction, surgical fracture fixation
Impaction Osteochondral/subchondral	Associated with hip dislocations, subchondral fracture line with marrow edema seen at MR imaging	If associated dislocation, prereduction radiography or emergent CT (see cell above); MR imaging or CT used to evaluate for occult fracture in high-risk/high-suspicion patients	THA in elderly patients, conservative clinical and imaging follow-up to exclude AVN
Femoral neck			
Subcapital and transcervical	Valgus impacted/nondisplaced Varus impacted (mushroom cap)/displaced carries high risk for AVN	Radiography with additional traction and internal rotation views often sufficient to characterize fracture line location, subsequent MR imaging or CT for indeterminate radiographs in high-suspicion patients to exclude radiographically occult fractures	ORIF in young patients, arthroplasty in elderly patients
Basicervical	Nondisplaced or displaced: relative low risk for AVN		ORIF
Femoral neck stress fracture			
Inferomedial cortex	Fatigue fracture, extensive marrow edema with cortical thickening and incomplete fracture line	Often occult at initial radiography, routine MR imaging in high-risk/high-suspicion patients	Protected weight bearing
Superolateral cortex	Insufficiency fracture (elderly patients) or fatigue fracture involving the "tension" side, high prevalence of displacement		ORIF
Intertrochanteric fracture			
	Older patients; generally low energy; fracture line extending from greater to lesser trochanter; displacement, comminution, calcar femorale involvement, subtrochanteric extension, and reverse obliquity are critical features; isolated lesser trochanter fractures are concerning for pathologic fractures	Initial radiography often sufficient for diagnosis, CT or MR imaging performed for incomplete fracture	ORIF
Subtrochanteric fracture			
Traumatic	Young patients: generally high energy, comminuted or spiral morphology; insufficiency fractures: low energy, less comminuted; piriformis fossa and lesser trochanteric involvement are critical features	Initial radiography often sufficient for diagnosis, CT or MR imaging performed for definitive fracture determination for preoperative planning	ORIF
Atypical	Transverse or oblique, no comminution, lateral cortical bump/thickening, often associated with long-term bisphosphonate therapy	Initial radiography often sufficient, but low threshold for MR imaging in high-risk/high-suspicion patients; contralateral limb is routinely imaged	ORIF, consideration of prophylactic fixation of incomplete fracture or contralateral limb lesion

Note.—ORIF = open reduction internal fixation.

femoral heads in patients 60 years old or older: differentiation of subchondral insufficiency fracture from osteonecrosis of the femoral head. AJR Am J Roentgenol 2010;195(1):W63–W68.
30. Shah AK, Eissler J, Radomisli T. Algorithms for the treatment of femoral neck fractures. Clin Orthop Relat Res 2002;(399):28–34.
31. Swiontkowski MF, Winquist RA, Hansen ST Jr. Fractures of the femoral neck in patients between the ages of twelve and forty-nine years. J Bone Joint Surg Am 1984;66(6):837–846.
32. Parkkari J, Kannus P, Palvanen M, et al. Majority of hip fractures occur as a result of a fall and impact on the greater trochanter of the femur: a prospective controlled hip fracture study with 206 consecutive patients. Calcif Tissue Int 1999;65(3):183–187.
33. Bartonícek J. Pauwels' classification of femoral neck fractures: correct interpretation of the original. J Orthop Trauma 2001;15(5):358–360.
34. Liporace F, Gaines R, Collinge C, Haidukewych GJ. Results of internal fixation of Pauwels type-3 vertical femoral neck fractures. J Bone Joint Surg Am 2008;90(8):1654–1659.
35. van Embden D, Roukema GR, Rhemrev SJ, Genelin F, Meylaerts SA. The Pauwels classification for intracapsular hip fractures: is it reliable? Injury 2011;42(11):1238–1240.
36. Damany DS, Parker MJ. Varus impacted intracapsular hip fractures. Injury 2005;36(5):627–629.
37. Ashman CJ, Yu JS. Hip and femoral shaft. In: Rogers LF, ed. Radiology of skeletal trauma. 3rd ed. New York, NY: Churchill Livingstone, 2002.
38. Kirby MW, Spritzer C. Radiographic detection of hip and pelvic fractures in the emergency department. AJR Am J Roentgenol 2010;194(4):1054–1060.
39. Khurana B, Okanobo H, Ossiani M, Ledbetter S, Al Dulaimy K, Sodickson A. Abbreviated MRI for patients presenting to the emergency department with hip pain. AJR Am J Roentgenol 2012;198(6):W581–W588.
40. Chen WC, Yu SW, Tseng IC, Su JY, Tu YK, Chen WJ. Treatment of undisplaced femoral neck fractures in the elderly. J Trauma 2005;58(5):1035–1039; discussion 1039.
41. Chandler HP, Reineck FT, Wixson RL, McCarthy JC. Total hip replacement in patients younger than thirty years old: a five-year follow-up study. J Bone Joint Surg Am 1981;63(9):1426–1434.
42. Heetveld MJ, Raaymakers EL, Luitse JS, Nijhof M, Gouma DJ. Femoral neck fractures: can physiologic status determine treatment choice? Clin Orthop Relat Res 2007;461:203–212.
43. Tidermark J, Ponzer S, Svensson O, Söderqvist A, Törnkvist H. Internal fixation compared with total hip replacement for displaced femoral neck fractures in the elderly: a randomised, controlled trial. J Bone Joint Surg Br 2003;85(3):380–388.
44. Mallick A, Parker MJ. Basal fractures of the femoral neck: intra- or extra-capsular. Injury 2004;35(10):989–993.
45. Egol KA, Koval KJ, Kummer F, Frankel VH. Stress fractures of the femoral neck. Clin Orthop Relat Res 1998;(348):72–78.
46. Fullerton LR Jr, Snowdy HA. Femoral neck stress fractures. Am J Sports Med 1988;16(4):365–377.
47. Weinlein JC. Fractures and dislocations of the hip. In: Canale ST, Beaty JH, eds. Campbell's operative orthopaedics. 12th ed. Philadelphia, Pa: Mosby, 2012; 2725–2777.
48. Deutsch AL, Coel MN, Mink JH. Imaging of stress injuries to bone: radiography, scintigraphy, and MR imaging. Clin Sports Med 1997;16(2):275–290.
49. Fredericson M, Bergman AG, Hoffman KL, Dillingham MS. Tibial stress reaction in runners: correlation of clinical symptoms and scintigraphy with a new magnetic resonance imaging grading system. Am J Sports Med 1995;23(4):472–481.
50. Kannus P, Niemi S, Parkkari J, Palvanen M, Vuori I, Järvinen M. Nationwide decline in incidence of hip fracture. J Bone Miner Res 2006;21(12):1836–1838.
51. Zain Elabdien BS, Olerud S, Karlström G. The influence of age on the morphology of trochanteric fracture. Arch Orthop Trauma Surg 1984;103(3):156–161.
52. Greenspan SL, Myers ER, Maitland LA, Kido TH, Krasnow MB, Hayes WC. Trochanteric bone mineral density is associated with type of hip fracture in the elderly. J Bone Miner Res 1994;9(12):1889–1894.
53. Kaufer H. Mechanics of the treatment of hip injuries. Clin Orthop Relat Res 1980;(146):53–61.
54. van Embden D, Rhemrev SJ, Meylaerts SA, Roukema GR. The comparison of two classifications for trochanteric femur fractures: the AO/ASIF classification and the Jensen classification. Injury 2010;41(4):377–381.
55. Evans EM. The treatment of trochanteric fractures of the femur. J Bone Joint Surg Br 1949;31B(2):190–203.
56. Jensen JS. Classification of trochanteric fractures. Acta Orthop Scand 1980;51(5):803–810.
57. Gdalevich M, Cohen D, Yosef D, Tauber C. Morbidity and mortality after hip fracture: the impact of operative delay. Arch Orthop Trauma Surg 2004;124(5):334–340.
58. McGuire KJ, Bernstein J, Polsky D, Silber JH. The 2004 Marshall Urist award: delays until surgery after hip fracture increases mortality. Clin Orthop Relat Res 2004;(428):294–301.
59. Forte ML, Virnig BA, Kane RL, et al. Geographic variation in device use for intertrochanteric hip fractures. J Bone Joint Surg Am 2008;90(4):691–699.
60. Anglen JO, Weinstein JN; American Board of Orthopaedic Surgery Research Committee. Nail or plate fixation of intertrochanteric hip fractures: changing pattern of practice—a review of the American Board of Orthopaedic Surgery Database. J Bone Joint Surg Am 2008;90(4):700–707.
61. Adams CI, Robinson CM, Court-Brown CM, McQueen MM. Prospective randomized controlled trial of an intramedullary nail versus dynamic screw and plate for intertrochanteric fractures of the femur. J Orthop Trauma 2001;15(6):394–400.
62. Bhandari M, Schemitsch E, Jönsson A, Zlowodzki M, Haidukewych GJ. Gamma nails revisited: gamma nails versus compression hip screws in the management of intertrochanteric fractures of the hip—a meta-analysis. J Orthop Trauma 2009;23(6):460–464.
63. Schultz E, Miller TT, Boruchov SD, Schmell EB, Toledano B. Incomplete intertrochanteric fractures: imaging features and clinical management. Radiology 1999;211(1):237–240.
64. Reiter M, O'Brien SD, Bui-Mansfield LT, Alderete J. Greater trochanteric fracture with occult intertrochanteric extension. Emerg Radiol 2013;20(5):469–472.
65. Lee KH, Kim HM, Kim YS, et al. Isolated fractures of the greater trochanter with occult intertrochanteric extension. Arch Orthop Trauma Surg 2010;130(10):1275–1280.
66. Feldman F Sr, Staron RB. MRI of seemingly isolated greater trochanteric fractures. AJR Am J Roentgenol 2004;183(2):323–329.
67. James SL, Davies AM. Atraumatic avulsion of the lesser trochanter as an indicator of tumour infiltration. Eur Radiol 2006;16(2):512–514.
68. Bedi A, Toan Le T. Subtrochanteric femur fractures. Orthop Clin North Am 2004;35(4):473–483.
69. Loizou CL, McNamara I, Ahmed K, Pryor GA, Parker MJ. Classification of subtrochanteric femoral fractures. Injury 2010;41(7):739–745.
70. Unnanuntana A, Saleh A, Mensah KA, Kleimeyer JP, Lane JM. Atypical femoral fractures: what do we know about them? AAOS Exhibit Selection. J Bone Joint Surg Am 2013;95(2):e8 1–13.
71. Weil YA, Rivkin G, Safran O, Liebergall M, Foldes AJ. The outcome of surgically treated femur fractures associated with long-term bisphosphonate use. J Trauma 2011;71(1):186–190.
72. Chiang CY, Zebaze RM, Ghasem-Zadeh A, Iuliano-Burns S, Hardidge A, Seeman E. Teriparatide improves bone quality and healing of atypical femoral fractures associated with bisphosphonate therapy. Bone 2013;52(1):360–365.
73. Lee YK, Ha YC, Kang BJ, Chang JS, Koo KH. Predicting need for fixation of atypical femoral fracture. J Clin Endocrinol Metab 2013;98(7):2742–2745.
74. Weaver MJ, Miller MA, Vrahas MS. The orthopaedic implications of diphosphonate therapy. J Am Acad Orthop Surg 2010;18(6):367–374.